



EFFECT OF BISPHOSPHONATES ON ORTHODONTIC TOOTH MOVEMENT IN OSTEOPOROTIC PATIENTS WITH MAXILLOFACIAL RADIOLOGICAL POINT: A SYSTEMATIC REVIEW

Abbassi Samareh¹, Tajbakhsh Neda²

1. DDS, oral and Maxillofacial Radiology, Board certified former Assistant Professor of oral & Maxillofacial Radiology, Hormozgan university of Medical Sciences, Iran.
2. DDS, School of Dentistry, Islamic Azad University Tehran, Dental Branch, Tehran, Iran.

Received: 03/14/2025
Accepted: 04/10/2025

EMAIL: tajbakhshneda979@gmail.com

ABSTRACT

Osteonecrosis is a lateral complication in patients receiving base phosphonates. This complication rarely occurs; if it does, it can cause serious problems for patients and can even lead to pathological fractures in the mandibular. It is aimed to evaluate the effect of bisphosphonates on orthodontic tooth movement in osteoporotic patients with maxillofacial radiological point. For this, 64 articles published between January 2004 and November 2024 in the Scopus Wiley Online Library, Web of Science, Cochrane Central Register of Controlled Trials, EBSCO, ISI, Elsevier,



and the Google Scholar search engine were reviewed using relevant keywords ("Orthodontics," "Base Phosphonates," "Osteoporotic patients"). Osteoporosis can create unique challenges for dental treatments. There are unlikely to exist medications that stimulate dental movements. Nonetheless, while some efforts are currently being made to develop a few medicines, their application has not yet accelerated orthodontic treatment. However, some medications slow toothpaste in the treatment of orthodontics that may be unintentionally used by the patient. These drugs are the processes of glandin, such as NSAIDS (analgesic drugs: ibuprofen, aspirin, and naproxen), which can lead to a decrease in tooth movement and subsequently prolong the duration of orthodontic treatment. Therefore, people in the process of orthodontic treatment should avoid continuous use of these non-steroidal anti-inflammatory drugs, or so-called NSAIDS. Individuals undergoing orthodontic treatment ought to substitute these painkillers with acetaminophen in order to prevent dental movements from impairing them.

KEYWORDS: Orthodontics; Base Phosphonates; Osteoporotic patients.

**EFFECTO DE LOS BIFOSFONATOS SOBRE EL MOVIMIENTO DENTARIO
ORTODÓNCICO EN PACIENTES OSTEOPORÓTICOS CON PUNTO
RADIOLÓGICO MAXILOFACIAL: UNA REVISIÓN SISTEMÁTICA**



RESUMEN

La osteonecrosis es una complicación lateral en pacientes que reciben fosfonatos básicos. Esta complicación es poco frecuente; de ocurrir, puede causar problemas graves a los pacientes e incluso provocar fracturas patológicas mandibulares. El objetivo es evaluar el efecto de los bifosfonatos en el movimiento dental ortodóncico en pacientes osteoporóticos con un punto radiológico maxilofacial. Para ello, se revisaron 64 artículos publicados entre enero de 2004 y noviembre de 2024 en Scopus Wiley Online Library, Web of Science, el Registro Cochrane Central de Ensayos Controlados, EBSCO, ISI, Elsevier y el motor de búsqueda Google Académico, utilizando palabras clave relevantes ("Ortodoncia", "Fosfonatos básicos", "Pacientes osteoporóticos"). La osteoporosis puede plantear desafíos únicos para los tratamientos odontológicos. Es poco probable que existan medicamentos que estimulen los movimientos dentales. No obstante, si bien se están realizando esfuerzos para desarrollar algunos medicamentos, su aplicación aún no ha acelerado el tratamiento ortodóncico. Sin embargo, algunos medicamentos ralentizan el efecto de la pasta dental durante el tratamiento de ortodoncia, lo cual puede ser utilizado involuntariamente por el paciente. Estos medicamentos, como los AINE (analgésicos: ibuprofeno, aspirina y naproxeno), son productos de la glandina, lo que puede provocar una disminución del movimiento dental y, en consecuencia, prolongar la duración del tratamiento de ortodoncia. Por lo tanto, quienes se someten a un tratamiento de ortodoncia deben evitar el uso continuo de estos antiinflamatorios no esteroideos (AINE).



Quienes se someten a un tratamiento de ortodoncia deben sustituir estos analgésicos por acetaminofén para evitar que los movimientos dentales los afecten.

PALABRAS CLAVE: Ortodoncia; Fosfonatos de base; Pacientes osteoporóticos.

INTRODUCTION

Osteoporosis, also known as elevated bone mass, is a pathological condition characterized by an increased susceptibility to tooth loss [1-3]. These types of bones can be easily broken or in the form of a pathological status as they do not have the flexibility and the strength of the healthy bones. An additional concern pertains to the intravenous injection of base phosphonate, a medication commonly prescribed for the management of osteoporosis that is becoming more prevalent among women; this drug induces a condition known as ONJ Syndrome [4]. This syndrome is

characterized by the death or deterioration of minute portions of the maxillary bone. The teeth situated in these anatomical regions have the potential to induce bone loss; furthermore, applying pressure to these bones can result in excruciating pain [5]. It is unimportant to mention that jawbone destruction may also occur [6].

Although many of these have been associated with tooth extraction or dental trauma, some lesions appear to have spontaneously occurred. Should the implant be utilized or tooth extraction be necessary as part of the treatment plan, it may be



necessary to postpone the resolution of osteoporosis. A class of synthetic base phosphonates comprises analogous pyrophosphate samples, such as extremely potent medications designed to obstruct bone analysis [7]. They exhibit a striking resemblance to calcium, are either endogenously stored in the bone or eliminated via urine. Due to the absence of bass phosphonate, its elevated concentration will persist in the bone indefinitely [8]. While there is ongoing research into the mechanism of base phosphonates, certain fundamental pathological physiologists are able to comprehend it. Due to the mixture of components, base phosphonates adhere to the bone and are subsequently consumed by osteoclasts. Osteoclast digestion of bass phosphonates induces apoptosis, also known as programmed cell death. Osteoblasts

additionally impede the absorption of osteoclasts [9]. Unavoidably, base phosphonates have an effect. In the case of hypercalcemia (an elevated blood calcium level), osteitis deformans (bone disease), the spread of bone disease (with or without hypercalcemia), and the presence of multiple malignant tumors of bone marrow cells, these conditions are treated intravenously. Oral administration is the only approach taken to treat osteoporosis. In all situations, dental interventions are not restricted. Millions of women who experience menopause prior to or following menopause are orally administered osteogenesis-related skeletal accidents preventative measures [10].

Thousands of patients also receive base phosphonate as part of their chemotherapy



diet to treat malignant diseases. Similarly, some people intend to benefit from dental treatments despite their diseases and bisphosphonate. Patient prognosis improves when surgical procedures and dental implants are excluded from the treatment plan. This is critical information that every dentist must be aware of for the aforementioned reasons [11].

Steroids (formerly known as corticosteroids or cortisone), which are hormones secreted naturally by the adrenal gland cortisol, are substances that inhibit the body's immune system, body, and relative immune systems [12]. These compounds reduce inflammation and exert a suppressive effect on the immune system. Histamine secretion is responsible for both cellular division and DNA synthesis. Humans produce steroids, which

are chemically identical to "Corticosteroid" and function similarly to the "Cortisol body"; they are utilized in a variety of medical applications and the treatment of maladies [13-15]. Athletes use anabolic steroids, which are composed of growth hormone and testosterone. These substances are quite distinct from the latter. Various formulations of steroid medications (oral, injectable, suppository, nasal spray, drops, and ointments) may be prescribed in accordance with the nature and intensity of the ailment. Prominent pharmaceuticals that are widely recognized include prednisolone, hydrocortisone, triamcinolone, and betamethasone. Similar to foods and other medications, these have potential side effects that can be mitigated through appropriate usage.



Methods

Between January 2004 and November 2024, the international databases MEDLINE (PubMed and Ovid), Embase and Cochrane were searched for scientific evidence for effect of bisphosphonates on orthodontic tooth movement in osteoporotic patients with maxillofacial radiological point using relevant keywords ("Orthodontics", "Base Phosphonates", "Osteoporotic patients "). Scopus Wiley Online Library, Web of Science, Cochrane Central Register of Controlled Trials, EBSCO, ISI, Elsevier and the Google Scholar search engine were also used. Inclusion criteria for studies in this research were articles published in English. Data not reported in orthodontic tooth movement in osteoporotic patient category were excluded from the study. Two researchers separately collected data from

subjects using a standard data collection form designed in advance to reduce reporting, data collection errors, and omissions

Results

The initial search identified 64 articles. In the first phase, 12 articles were eliminated due to duplicate records based on article titles. Studies that did not meet the inclusion criteria were excluded by reviewing the abstracts of 52 articles in the second step (n = 27). In the third step, 13 articles with incomplete data or non-compliance with the inclusion and exclusion criteria were eliminated after examining the full texts of 20 articles. Ultimately, 12 articles were included in the present study (Fig. 1 and Table 1).

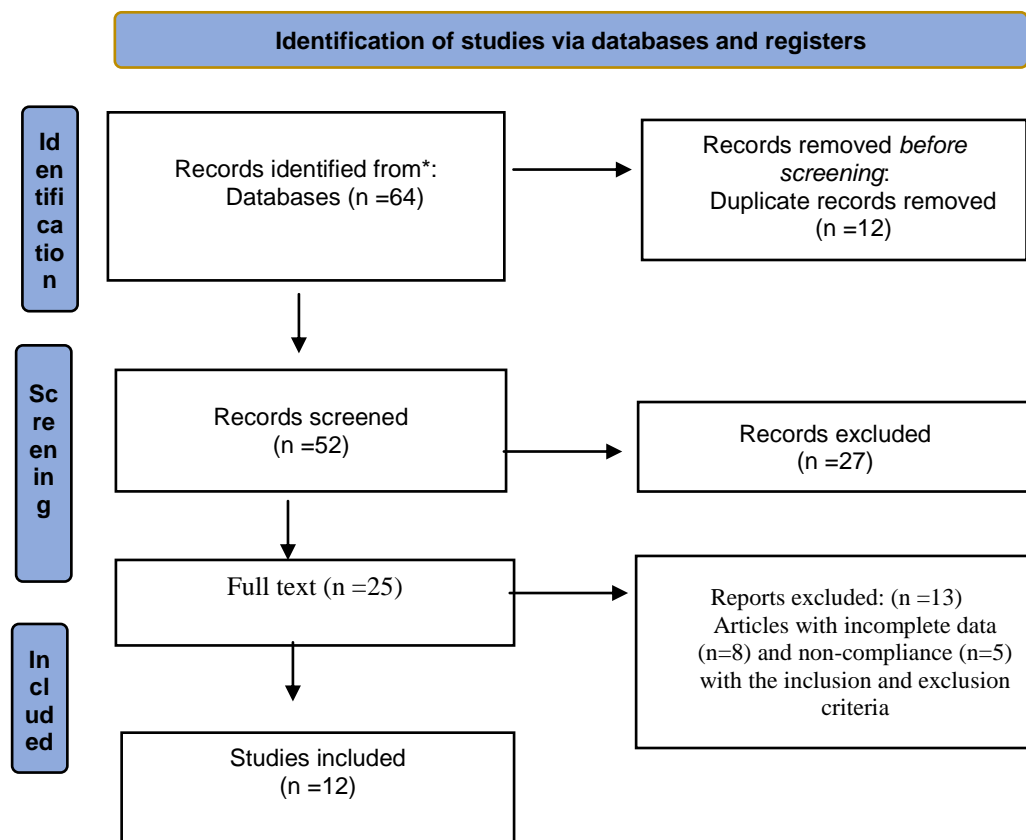

















Figure 1. Flow PRISMA 2020 of included subjects

Raw	Study	Year		Proportion Wight 98%		Weight %
1	Naghdipour et al.	2021		0.92	[0.9 – 1.06]	4.02
2	Motamedi et al.	2023		0.87	[0.4 – 1.02]	4.21
3	Milanifard et al.	2021		0.88	[0.3 – 1.01]	3.25
4	Kheradjoo et al.,	2022		0.60	[0.5 – 1.8]	5.75
Heterogeneity $\tau^2=0.04$, $I^2= 0.02$, $H^2=1.2$				0.95	[0.2 – 1.07]	
Test of $\Theta= \Theta$, $Q (4) =3.45$, $P= 0.44$						
1	Rodríguez et al.	2017		0.84	[0.7 – 1.08]	4.3
2	Yasrebinia et al.	2024		0.76	[0.2 – 0.42]	4.05
3	Otaghvar et al.	2023		0.11	[0.4 – 0.9]	4.03
4	Naghdipour et al.	2022		0.39	[0.2 – 0.9]	5.04
Heterogeneity $\tau^2=0.1$, $I^2= 0.11$, $H^2=0.22$				0.77	[0.9 – 1.00]	
Test of $\Theta= \Theta$, $Q (4) =3.15$, $P= 0.4$						
1	Nokoff et al.	2019		0.92	[0.9 – 1.06]	4.6
2	Tanaka et al.	2001		0.87	[0.4 – 1.02]	5.3
3	Antunes et al.	2009		0.99	[0.63 – 1.01]	6.1
4	Nokoff et al.	2019		0.68	[0.25 – 1.08]	3.9
Heterogeneity $\tau^2=0.4$, $I^2= 0.00$, $H^2=1.00$				0.87	[0.22 – 1.07]	
Test of $\Theta= \Theta$, $Q (4) =3.5$, $P= 0.2$						



Relapse is an unpredictable risk factor for every patient. Before starting treatment, patients should be informed about the risk of relapse in the long term and ways to reduce it. Some of the causes of relapse are under the control of the orthodontist, but others, such as soft tissue changes and delayed growth, are not under the management of the therapist and may therefore be responsible for changes in the position of the teeth in the long term. Therefore, retention after ortho treatment is recommended by researchers and orthodontists. The purpose of retention is to keep the teeth in their correct place after the treatment.

A medical condition characterized by bone tissue deterioration; osteoporosis elevates the likelihood of suffering a fracture. Although

osteoporosis is frequently linked to advancing age, it can manifest in younger individuals because of certain maladies or genetic predispositions. Orthodontic treatment may be complicated by osteoporosis due to the immobility of the teeth in the bones [3].

Osteoporosis is a pathological state characterized by brittle and permeable bones. Frequently referred to as "Silent disease" due to its undetectability prior to the occurrence of the fracture. Orthodontic treatment may be impacted by two primary forms of osteoporosis: secondary osteoporosis and primary osteoporosis [4].

Early osteoporosis: This variant of osteoporosis predominantly impacts elderly men and postmenopausal women. This is the



result of age-related reductions in bone mass and density. Women are more prone to developing this form of osteoporosis due to the accelerated rate of bone mass loss following menopause in comparison to men. Lifestyle modifications, including regular exercise, a balanced diet rich in calcium and vitamin D, and abstinence from smoking and excessive alcohol consumption, have the potential to regulate this particular form of osteoporosis [15].

Secondary osteoporosis: This form of osteoporosis can be attributed to diseases such as kidney failure or thyroid disorders, as well as deficiencies in certain vitamins or hormones. Medication used to treat underlying diseases or to replace hormone or vitamin deficiencies can effectively manage secondary osteoporosis. In this form of

osteoporosis, orthodontic braids may provide additional tooth support and prevent bone atrophy. Additionally, good oral hygiene can aid in the prevention of periodontal disease and tooth decay [16-18].

It is noteworthy that despite the disease's predominant impact on the skeletal system, a considerable number of individuals remain oblivious to its potential ramifications on dental health. Insufficient bone strength and the presence of porous bone materials can result in dental complications. Base phosphonates, which are frequently prescribed for the management of osteoporosis, have the potential to induce a condition known as the Jaw Syndrome (ONJ Syndrome) [7]. ONJ syndrome is distinguished by the presence of necrosis (death of tissue) and limited fragmentation



of the maxillary bone. The teeth in these regions may be displaced or fallen, resulting in excruciating agony when pressure is applied. Moreover, damage to the mandible is possible [19].

Orthodontic treatments often need pressure on the teeth, which may cause damage if the underlying bone structure is damaged [9]. In order to determine whether osteoporosis is severe enough to impede orthodontic treatment, the condition of the bones, particularly those surrounding the teeth, must be evaluated. There exist multiple approaches to assessing this matter:

Determining osteoporosis in the vicinity of a tooth is one method. This is possible through the use of contemporary dental imaging methods, such as tumor computation with

CBCT. The density of succulent bones is assessed and contrasted. A notable decrease in bone density may serve as an indicator of advanced osteoporosis, which has the potential to impact orthodontic treatment [1]. Notably, these procedures must be carried out under the supervision of a qualified specialist, as erroneous interpretation may result in an erroneous diagnosis. They possess the ability to provide guidance in the assessment of the disease's severity and its potential impact on orthodontic treatment.

In patients with severe osteoporosis, the efficacy of orthodontic treatment is largely determined by the type of osteoporosis and the patient's overall health. No particular orthodontic treatment demonstrates ubiquitous superior efficacy in managing severe osteoporosis. However, specific orthodontic treatments may have a lesser



effect on exacerbation. The following factors may be taken into account in light of the information at hand:

Non-surgical orthodontic treatments, such as braids and preservatives, usually include less pressure on the teeth and the surrounding bone structure. This makes them less helpful to losing bone or complicating osteoporosis [10].

When surgical intervention is necessary, it may be advantageous to employ the minimum trauma approach. During surgery, this technique reduces the amount of pressure exerted on the teeth and adjacent structures. It can also assist in preserving the maximum amount of the existing bone structure [20].

Regular monitoring of the patient's bone health and regulating an orthodontic treatment program can also be helpful. This allows for early detection of potential problems and the ability to make the necessary changes to prevent further damage. Several factors influence tooth movement, including chemical and physical reactions of the body, certain cellular changes that occur during orthodontic treatment, and both the rate and manner in which the teeth move.

Orthodontics induces tolerance in the jaw and dental structure, causing the jaw and teeth to realign to their proper positions. This may induce vasodilation and inflammation, resulting in elevated blood flow to the affected areas. Treating orthodontics is either simpler or more complicated [2].



Variables present in an individual's blood can have an impact on the duration of orthodontic treatment. The substance enters the patient's bloodstream upon administration and can significantly affect metabolism and overall bodily activity. Certain substances exhibit a deterrent effect on tooth movement, thereby shortening the duration of orthodontic treatment. Others, on the other hand, accelerate the rate of tooth movement [13].

The subsequent pharmaceutical interventions may significantly influence the course of this treatment by acting as analgesics and stimulating mandible and tooth movement: Adenosine mono phosphate, Calcium [14], Collagen, Prostaglandin

The medications can enhance the mobility of the teeth and mandible and significantly

alleviate the discomfort associated with orthodontic treatment [21].

Medications that have a negative effect on this treatment are:

1. Ibuprofen: Although housing drugs such as ibuprofen can relieve pain, they have a deterrent role on teeth.

2. Non-steroidal drugs and corticosteroids: The rate of tooth movement has been diminished through the use of non-steroidal analgesics and corticosteroids, which accomplish this by inhibiting prostaglandins.

With continued use of these medications, the patient's teeth may become immobile. Individuals who consume corticosteroids or similar medications for any reason are therefore ineligible for orthodontic treatment [22].



3. Aspirin, Tramadol, Diclofenac, Indomethacin, and Morphine: These drugs can sometimes disrupt the treatment process and slow down the speed of tooth movement.

4. Lessenen: It delays the treatment process and reduces the speed of tooth movement.

5. Indomethacin: This drug can be an effective factor in slowing teeth [7].

Acetaminophen is composed of central nervous system-influencing substances. Acetaminophen, unlike other analgesics, exhibits minimal impact on the rate of dental movement. Consequently, it may serve as a viable alternative for alleviating orthodontic discomfort.

Anti -sophisticated drugs such as amitriptyline, doxepine can reduce the speed

of tooth movement in orthodontic treatment [8].

Dental movement can be impeded by phosphonate-based medications administered at its base. Patients who are postmenopausal or have osteoporosis are the primary demographics for these medications. To facilitate orthodontic treatment initiation, individuals who are menopausal or have bone osteoporosis and are considering menopause should inform their orthodontists about their medication usage so that adjustments can be made [3].

Consuming vitamins and dietary supplements have no negative impact on this treatment and has no problem using them during treatment.

Preventing the discontinuation of medications during the course of treatment is



not obligatory. However, the orthodontist's opinion is extremely important, and depending on the type of medication, it is probable that different decisions will be made for each individual [10].

Discussion

Osteoporosis may be clinically classified as an unjustifiable fracture or the absence of a compression or fracture threshold, as evidenced by a reduction in bone mass that elevates the risk of fracture. Even when bone density is decreased [23], bone failure does not always result. Fracture susceptibility can be induced by various aging-related factors, such as compromised neurological-motor coordination, advanced age, arthritis, Parkinson's disease, and more [24-26].

Base phosphonate drugs have indications for a wide range of diseases, including

malignancy hypercalcemia, prevention of bone metastasis of solid tumors such as breast and prostate cancers, multiple myeloma bone lesions, osteoporosis control, osteopenia [27-29]. By impeding the osteoclasts' assimilation of trabecular bone, base phosphonates disrupt the process of bone circulation, resulting in the maintenance of bone density and a reduction in angiogenesis and blood supply [30]. As a consequence, routine surgical procedures, including tooth extraction, may induce bone protrusion into the oral environment, infection, discomfort, and in more severe instances, even severe complications [31]. These instances diminish the patient's quality of life and require intervention for both prevention and treatment. In addition to clinical evidence, radiation findings, and histological analysis, a comprehensive



patient history should be considered when diagnosing this injury [32]. Acute wounds, pain, mucosal edema, erythema, and mucosal swelling are all clinical manifestations. Occasionally, hyperoposy or low-lip anastosis is described as the initial significant indication of this lower mandible complication [33].

In the upper jaw, MRONJ may also be seen in patients with chronic secondary sinusitis with or without oral-sinusoidal fistulas [34]. Unfortunately, more than 15 years after the first report, no definitive treatment has been discovered yet [33-35]. The routine and the initial treatment involve the removal of necrosis bone and systemic antibiotic administration as well as disinfectant solutions. Laser therapy, ozone therapy, hyperbaric oxygen, and autologous platelet

concentrates (APCS) are examples of more recent techniques [36-38]. APCs have the ability to produce growth factors, including epidermal development factor, endothelial growth factor, and invoice factor. These growth factors stimulate the release of fibroblasts and beta-1 growth factor, ultimately aiding in the acceleration of the wound healing process [39]. A systematic investigation has demonstrated that the application of APCs significantly ameliorates MRONJ lesions [40]. For the first time in 1991, APCs were used in oral surgery to improve bone and in 2007 to help improve the bone improvement of routine MRONJ [41]. APCs utilized in the management of MRONJ generally fall into three categories: platelet-rich plasma (PRP), plasma-rich in growth factors (PRGF), and platelet-rich fibrin. PRFs represent the



subsequent iteration of the APC family, which was initially proposed by Choukorm et al. [42] Platelets, leukocytes, and fiber, all of which are abundant in PRFs, promote the healing of bone lesions. Recent research indicates that orthopedic medications frequently prescribed for osteoporosis might negatively impact dental implants [43].

Dentists ought to be informed that certain medications have the potential to induce numerous oral complications. 40% of individuals suffer from dry mouth syndrome (Zeroostomia, Xerostomia), one of the most prevalent conditions [44]. The medications prescribed by Zeroostomia are not, however, the only medications that dentists should be concerned about [45-47].

Typically, base phosphonate is administered to treat osteoporosis and other conditions

characterized by a loss of initial bone cohesion; it prevents fractures and other injuries [48]. The impact of this medication on the mandible was investigated by the researchers, who also noted that base phosphonates had an effect on the jawbone's aesthetic appeal [49-51]. Although implants are typically predictable, alterations in the structure of the bone can cause severe implant injury [52-54]. Twenty-five patients with osteoporosis who were at least sixty years old were evaluated. All of the patients included in this investigation had undergone implant surgery at the outset [55-57]. Eleven of the twenty-five patients were prescribed base phosphonate for one year, while hormonal treatment was utilized in lieu of medication for the remaining fourteen. Both groups then conducted an examination of the peripheral bone thickness and mineral



density of the bone [58]. The implant of three individuals was compromised by bisphosphonate-treated patients [59-61]. The implant, however, remained healthy in the fourteen patients who refrained from using the medication [61-64]. It was observed that the girth of the outer bone and the mineral density of the bones increased in the group that ingested base phosphonate.

Conclusion

According to the results treatment with base phosphonates has an impact on outer bone and the mineral density of cortical bone in osteoporosis patients with posterior mandibular infections. Certain drugs slow down the use of toothpaste in orthodontic treatment, which the patient may inadvertently use. NSAIDS (analgesic drugs: ibuprofen, aspirin, and naproxen) are

examples of glandin-related medications that can cause a reduction in tooth movement and, as a result, lengthen the orthodontic treatment period. Thus, individuals undergoing orthodontic treatment should refrain from using these so-called NSAIDS (non-steroidal anti-inflammatory drugs) on a regular basis. In order to keep their teeth from movement, people getting orthodontic treatment should take acetaminophen instead of these painkillers.

REFERENCES

1. A Biravand , A Feiz, A Gholamian, N Niroomand , N Shams ,S Abbasi Dezfouli. Comparison of Amount of Microleakage from Core Composite Following Incremental and Bulk



Composite Build-up Techniques using
Clearfil Photo Core-Light Cure.
Jundishapur Scientific Medical Journal.
2015; 14(4): 411.

2. A Dabbaghi, A Habibi Kia, S Abbassi,
N Niroomand, S A Mohagheghi, S
Sharifi. Efficacy of Different Image
Processing Filters for the Detection of
Proximal Recurrent Caries in Digital
Bitewing Radiographs. Jundishapur
Scientific Medical Journal. 2015; 14(2):
157-168.

3. A Dabbaghi, S Abbassi, N Shams, N
Niroomand, A Habibi Kia. Efficacy of
image processing filters in the detection
of proximal caries in digital bitewing
radiograph. Jundishapur Scientific
Medical Journal. 2015; 14(2): 170-180.

4. A Feiz, A Gholamian, N Niroomand,
N Shams, S Abbasi Dezfooli, A
Biravand. Survey of Selected
Radiography Techniques used by Ahvaz
Dentists in Implant Treatment.
Jundishapur Scientific Medical Journal.
2015; 14(4): 404-410.

5. A Heydarian, BNF Azar, Acute
Abdomen Referred Management in
Emergency department, Eurasian Journal
of Chemical, Medicinal and Petroleum
Research, 2024, 3 (2), 411-423

6. A Ismaili, M Jafari, E Horri. General
Anatomy of Blood Vessels, Nervous
System and Respiratory System.2021;1:
108



7. A Rahat-Dahmardeh, H Esfahani, E Mohammadzadeh, M Jafari, S Keshmiri.

Rhabdomyolysis in COVID-19 Patients: A systematic Review and Meta-Analysis. International journal of early childhood special education. 2022; 14(02): 4019-4024.

8. A Shahbaz, N Tajbakhsh, A Doroudi, F Bakhshi, S Ranjbar. Bredigite-containing materials for regenerative medicine applications: A rapid review. Journal of Composites and Compounds. 2023; 5(16): 190-199

9. M Yazdizadeh, A Kia, S A Mohagheghi, A Basir, S Abbasi, N Nirooomand, S Aghajeri, M Shamsaei. Clinical Comparison of the accuracy of root canal length determination in

permanent teeth by means of Root ZX electronic apex locator, tactile perception and conventional . Jundishapur Scientific Medical Journal. 2014; 13(2): 181-190.

10. M Vakhshoori et al. The impact of platelet-to-lymphocyte ratio on clinical outcomes in heart failure: a systematic review and meta-analysis. 2024; 18

11. M Shooriabi, Ali Habibikia, S A Satvati, S A Mohagheghi, S Mawalizadeh, L Rajaei, S Abbasi. Evaluation of Glycemic Control and its Relationship with Dry Mouth in Patients with Diabetes Mellitus Referred to Ahvaz Dental School. Jundishapur Scientific Medical Journal. 2014; Supplement, p89-96. 8p



12. M Saboury et al. Underestimated craniomaxillofacial fractures due to firework. World journal of plastic surgery. Iran Society of Plastic, Reconstructive and Aesthetic Surgeons. 2021;10(3): 46

13. M Rassam, A Dehghani, R Azhough, Minimally Invasive hook circulators in Pilonidal Sinus Surgery and Postoperative Pain Outcomes, Eurasian Journal of Chemical, Medicinal and Petroleum Research, 2024, 3 (2), 424-433

14. M Oroei et al. The evaluation of head and neck neoplasm in young and old adults. Social Determinants of Health. 2019;5(2):117-125

15. M Motaqi, M Samadi, A Ghanjal, M Afrand. A New Approach to Evaluate of Musculoskeletal Pain. International Journal of Musculoskeletal Pain Prevention. 2022; 7(4): 781-787.

16. M Motaqi, M Afrand, A Ghanjal. Care and Management of Pain in Patients with Musculoskeletal Pain during the Covid-19 Epidemic. International Journal of Musculoskeletal Pain Prevention. 2022; 7(1): 622-626.

17. M Motaqi, A Ghanjal, M Afrand. Treadmill Exercise and its Effect on Rehabilitation of Patients after Ischemic stroke: A Narrative Study. international Journal of Musculoskeletal pain prevention. 2022; 7(3): 730-740.



18. Kh Ghasemi et al. Investigation of the prevalence of asymptomatic microscopic hematuria in primary school children of Bushehr and Kharg Island. Tebe Jonoob, 2004; 7(1): 54-60

19. H Soltani Nejad Roodabadi et al. The Use of Machine Learning in Supply Chain Management, A Systematic Review. IEOM Society International. 13th Annual International Conference on Industrial Engineering and Operations Management Manila, Philipines; March 7-9, 2023.
<https://doi.org/10.46254/AN13.20230529>

20. H Soltani Nejad Roodabadi et al. Enhancing Operational Efficiency: A Study on Lean Manufacturing Implementation in Small and Medium-

sized Enterprises. 8th North America Conference on Industrial Engineering and Operations Management, Houston, United States of America Publisher: IEOM Society International; June 13-15, 2023.

21. H Soltani et al. Achieving Excellence in SMEs: A Deep Dive into six sigma Methodologies for process Improvement. IEOM society International. proceedings of the 14th Annual international conference on Industrial and operations management Dubai, united Emirates(UAE), February 12-14, 2024

22. H Soltani et al. Optimizing Efficiency and standardization: A lean six sigma Approach in US small and Medium-sized



manufacturing_ A case study of
magnelab inc.proceedings of the 14th
Annual international conference on
Industrial and operations management
Dubai, united Emirates(UAE),February
12-14,2024

23. H Alizadeh Otaghvar et al. Medical
evaluation of the effectiveness and
outcome of regional anesthesia in burn
populations to reduce drug use: a
systematic review and meta-analysis.
Eurasian Chemical Communications.
Sami Publishing Company
(SPC).2022;4(6): 473-480

24. H Ahmady, M Afrand, M Motaqi, Gh
Hossein Meftahi. Utilizing Sertoli cell
transplantation as a therapeutic technique
for managing neurodegenerative diseases.

Archives of Razi Institute.2023;
0.22092/ARI.2023.363696.2884

25. F Hosseinzadegan, S Sarlak, S
Savoji, S A Ashkan Mousavi Chashmi, M
Sadeghian. Cardiovascular Diseases and
Relationship with Mortality and Severe
COVID-19 in Patients with COVID- 19:
A Systematic Review and Meta-Analysis.
International Journal of Special
Education. 2022;37(3): 12609-12617

26. B Shrestha et al. Role of 18F-FDG
PET/CT to evaluate the effects of
chimeric antigen receptor T-cell therapy
on lymph node involvement in patients
with non-Hodgkin lymphoma.Journal of
Nuclear Medicine.2023;64(1):1159



27. B Shrestha et al. Dual time-point imaging of lymphoma adenopathy using total-body FDG PET/CT. Journal of Nuclear Medicine.2023;64(1):1444

28. B Fazeli. A comprehensive overview of Neurological Diseases such as MS,Alzheimers, Guillain Barre and Myasthenia Gravis based on Drug therapy Tips in These patients.2023,164.

29. B Fazeli et al. A systematic Review the treatment and diagnose of neurological problem in fat patients adults involved infection with radiological point. International Neurology Journal.2024;28(1):423-433

30. AR Lotfi, A Dehghani, Pain Intensity and Mortality after Sinonasal

Mucormycosis Surgery, Eurasian Journal of Chemical, Medicinal and Petroleum Research, 2024, 3 (2), 454-459

31. M Saboury et al. Use of facial artery musculomucosal and turbinate flaps for Rapp Hodgkin syndrome. World Journal of Plastic Surgery.2022; 11(2): 153-156

32. M Sabouri et al. Prognostic Factors for Fournier's Gangrene; A 10-year Experience in Southeastern Iran. Bull Emerg Trauma journal. Trauma Research Center, Shiraz University of Medical Sciences.2013; 1(3): 116-122

33. M Shojaei et al. Correlation of serum adiponectin level with metabolic syndrome in postmenopausal women of



Bandar Bushehr: a population study.
Tebe Jonoob,2013;16(5): 276-287

Eurasian Journal of Chemical, Medicinal
and Petroleum Research.2024;3(1): 296-
306

34. M Shojaei. A Systematic Review of
the Effect and Safety of Alendronate on
Bone Density in Patients with Chronic
Kidney Disease. Eurasian Journal of
Chemical, Medicinal and Petroleum
Research.2024;3(2): 434-442

37. M Shojaei. CHAT-GPT and artificial
intelligence in Medical Endocrine System
and interventions. Eurasian Journal of
Chemical, Medicinal and Petroleum
Research.2024;3(1): 197-209

35. M Shojaei. A Systematic Review of
the Relationship between Sex Hormones
and Leptin and Insulin Resistance in
Men. Eurasian Journal of Chemical,
Medicinal and Petroleum
Research.2024;3(2): 443-453

38. M Shojaei. The Effects of esreradiol
on leptin and other factors. Eurasian
Journal of Chemical, Medicinal and
Petroleum Research..2024;3(1): 131-141

36. M Shojaei. Alternative Systematic
Review of Insulin Resistance and the
Role of Sex Steroids on Leptin Levels.

39. M Reza Akhoondinasab et al. The
comparison of a new durable
coronaplasty technique with Norfolk
method for glans reconstruction after
phalloplasty. World journal of plastic



surgery. Iran Society of Plastic, Reconstructive and Aesthetic Surgeons.2020; 9(1): 39

40. M Dahmardehei et al. Comparison of Modified Meek Technique with Standard Mesh Method in Patients with Third Degree Burns. World Journal of Plastic Surgery. Iran Society of Plastic, Reconstructive and Aesthetic Surgeons.2020;9(3): 267

41. N Behdadian, Z Seraj, M Jafari, A Arabkhazaie, A Shams. Treatment Measures in the Face of Viruses, Infectious Diseases and Patients under Plastic Surgery with Impact on Causing Skin Diseases and Its Challenges: The Original Article. Tobacco Regulatory Science.2022;8(1)

42. N Motamedi et al. PET imaging in pediatric oncology: A Narrative Review. Journal of Nuclear Medicine.2023;64(1):1179

43. N Shams, N Niroomand, M Moradinezhad, S Abbasi, A Habibi Kia, B Shams. Effects of Digital Image Processing Filters on Detection of Lateral Cephalometric Landmarks. Jundishapur Scientific Medical Journal. 2015; 14(3): 354-366.

44. N Tajbakhsh, F Delpisheh, N Ghadimi, S Ansari. Smile management: White esthetic, pink esthetic and facial attractiveness, a review of literature. Open Access Research Journal of



Biology and Pharmacy. 2022; 5(2): 046-050.

45. Sh Mashaei, SA Ashkan Mousavi Chashmi, S Savoji, R Alimoradzadeh, S Javanmard Barbin. Rhabdomyolysis in COVID-19 Infection: A Systematic Review and Meta-Analysis. International Journal of Special Education. 2022;37(03): 12618-12625

46. Sh Mashaei, A Karimkoshteh, S. A A Mousavi Chashmi, R Alimoradzadeh, M Vafadar. Respiratory Physiotherapy and respiratory therapies in patients with COVID-19: A systematic review and meta-analysis. International Journal of Special Education. 2022;37(03): 12655-12662

47. Sh Heshmatollah et al. Effect and safety of alendronate on bone density in patients with chronic kidney disease; a controlled double blind randomized clinical trial. Journal of Parathyroid Disease,2016;4(1): 3-6

48. SA A Mousavi Chashmi. A Comprehensive Overview of the Diagnosis and Treatment of Wounds based on the Tips of Various Dressings and Surgical Methods.2023;1(116): 978-620-6-17681-7

49. S Sharifi Shooshtari, N Niroomand, M Kazemnezhad, s Abbassi, A Habibi kia, F Sedaghat. Evaluation and Comparison of the Diagnostic Accuracy of Indirect Digital Radiography (PSP) and Conventional Radiography in



Periapical Lesions. Jundishapur Sci Med J. 2015; 14(3): 333-341.

50. S Sayad et al.comprehensive investigation of radio-oncology in breast cancer patients based on psychological and radiological problem in these.Pakistan heart journal.2024;57(1)

51. S Sayad et al.comprehensive evaluation of radiation oncology,medical and nursing care treatment in women with breast cancer based on sonographic and radiological points.Pakistan heart journal.2024;57(1)

52. S S Shoostari, S Abbassi, S Fattahian, N Niroomand, A Habibi Kia, M Azizian, N Panahandeh, S Harandi. Evaluation of the Diagnostic Accuracy of

Indirect Conventional and Inverted Processing Digital (PSP) Radiograph Images in Periapical Lesions. Jundishapur Scientific Medical Journal. 2015; 14(3): 263-272.

53. S Nasrollazadeh, B Nazari, M Irajian, The role of dorsal blocking pinning for range of motion change of PIP joint after volar plate arthroplasty, Eurasian Journal of Chemical, Medicinal and Petroleum Research, 2024, 3 (2), 390-400

54. S Naderi Gharahgheshlagh et al. Fabricating modified cotton wound dressing via exopolysaccharide-incorporated marine collagen nanofibers. PublisherElsevier. Materials Today Communications.2024;39: 108706



55. S Keshmiri, S A Ashkan Mousavi Chashmi, N Abdi, E Mohammadzadeh, S Javanmard Barbin. Systematic Evaluation of Wound Healing and Easy Intubation Rate in Children with Covid-19 and Hospitalization in Intensive care Units: A Systematic Study. International Journal of Early Childhood Special Education.2022;14(1): 2960-2970

56. S Haghnegahdar, P Jafarnejadi, A Ahangarpour, M Gooran, S Abbassi. Evaluation of Salivary Melatonin in Patients with Oral Lichen Planus Referring to Dentistry Faculty of Jundishapur Ahvaz University at 2011-2012. Jundishapur Scientific Medical Journal. 2015; 14(5): 563-571.

57. S Amirfarhangi, A Vakili, N Tajbakhsh. Golden proportion and facial esthetic, the harmony and surgical considerations: A review. World Journal of Biology Pharmacy and Health Sciences. 2022; 11(1): 018-021

58. S Abbassi, A Habibi Kia, S Hemmat, N Niroomand, M Esmaeili, H Ebrahimnejad. Nasopalatine duct cyst: A case report. Jundishapur Scientific Medical Journal.2015; 14(5): 606-614.

59. S Abbassi S Ahmadzadeh, M Abbassi. Separation of tooth crown from root in bitewing images using image processing (Persian/Farsi). The 2nd National Conference of New Technologies in Electrical & Electronics Engineering – Fasa (Iran).2014



60. S Abbassi S Ahmadzadeh, M Abbassi. Separation of teeth from bone in bitewing images using image processing (Persian/Farsi). The 2nd National Conference of New Technologies in Electrical & Electronics Engineering – Fasa (Iran). 2014

61. S Abbassi, S Ahmadzadeh, M Abbassi. Separation of teeth in bitewing images using image processing (Persian/Farsi). National Electronic Conference on Advances in Basic Sciences and Engineering – Ardabil (Iran).2014

62. S Abbassi, S Ahmadzadeh, M Abbassi. Detection of missing teeth in bitewing images using image processing (Persian/Farsi). National Electronic

Conference on Advances in Basic Sciences and Engineering – Ardabil (Iran).2014.

63. S Abaci Mahmood Jahangirnezhad, Saede Atarbashi Moghadam, Mahdi Pourmahdi Borujeni, Nepton Emad Mostofi, AmirAli Azimi. Immunohistochemical Analysis of p63 Marker Expression in Pleomorphic Adenoma and Mucoepidermoid Carcinoma of Salivary Gland (Persian/Farsi). Jundishapur Scientific Medical Journal. 2012; 11(5): 541-548.

64. P Maroufi, T Poulrak .Determination of pre-operative platelet levels with the bleeding during tibia fracture surgery .Eurasian Journal of Chemical, Medicinal



ACTA BIOCLINICA

Artículo de Revisión

Abbassi Samareh y Col.

Volumen 15, N° 30 Especial, 2025

Depósito Legal: PPI201102ME3815

ISSN: 2244-8136

and Petroleum Research, 2024, 3 (2),
401-410.