

Endodontic microbiota from oral and maxillofacial perspective – A systematic review (*Microbiota endodóntica desde la perspectiva oral y maxilofacial – Una revisión sistemática*)

Varalakshmi Parasuraman ¹, Karthik Shunmugavelu ²  , Evangeline Cynthia Dhinakaran ³  

¹ Conservative dentistry & Endodontics, Dept of Dental Surgery, Govt Vellore Medical College and Hospital, Vellore, India

² Department of Dentistry/Oral and Maxillofacial Pathology, PSP Medical College Hospital and Research Institute, India

³ Department of Pathology Sree Balaji Medical College and Hospital, Chrompet, Chennai-600044, Tamilnadu, India

Received: 17 de Enero de 2024.

Accepted: 30 de Junio de 2024.

Online publication: 31 de Julio de 2024.

[Review Manuscript]

PII: S2477-9369(24)13002-R

Abstract(english)


Oral microbiome is of diverse nature. Oral diseases are associated with oral dysbiosis. The demands can be met by recent advances in genomics and molecular biology. Multidisciplinary approach needs to be applied in case of management of such diseases, especially the lesions of endodontic origin. Oral microbiome is a double-edged weapon. The current review compiles oral microbiome in health and disease with a multidisciplinary dental approach. Management strategies based on therapeutic potential and prophylaxis are to be initiated from the researcher point of view. A detailed literature search was done pertaining to OMFP patients and their association with periapical pathology. Inclusion criteria include various studies done on the above based topics. We found a grand total of 300 cases were identified from 150 papers published in English language literature. Of these 150, 98 were filtered narrowing down to 52 fully downloaded studies pertaining to the topic. Finally, a perspective from an endodontist should be done in an exceptional way in patients with OMFP in order to achieve long-term success.

Keywords(english)

Oral and maxillofacial, pathology, endodontology, periapical, microbiome.

Resumen(español)

El microbioma oral es de naturaleza diversa. Las enfermedades bucales están asociadas con la disbiosis bucal. Las demandas pueden satisfacerse mediante avances recientes en genómica y biología molecular. Es necesario aplicar un enfoque

 **Autor de correspondencia:** Dr. Karthik Shunmugavelu. BDS, MDS OMFP, MSC LONDON, MFDSRCS ENGLAND, MFDSRCPs GLASGOW, FACULTY AFFILIATE RCS IRELAND, AFFILIATE RCS EDINBURGH, MCIP, FIBMS USA, MASID AUSTRALIA, Senior Resident / Consultant Dental Surgeon / Consultant Oral and Maxillofacial Pathologist, Department of Dentistry/Oral and Maxillofacial Pathology, PSP medical college hospital and research institute Tambaram Kanchipuram main road Oragadam Panruti Kanchipuram district Tamilnadu 631604, Mobile 0091-9789885622/9840023697
Dr Evangeline Cynthia Dhinakaran. MBBS MD PATHOLOGY, Senior Resident, Department of Pathology Sree Balaji Medical College and Hospital, Chrompet, Chennai-600044, Tamilnadu, India. Mobile – 9952054096, Email: drevangelinedhinakaran@gmail.com.

multidisciplinario en el caso del tratamiento de dichas enfermedades, especialmente las lesiones de origen endodóntico. El microbioma oral es un arma de doble filo. La revisión actual recopila el microbioma oral en salud y enfermedad con un enfoque odontológico multidisciplinario. Desde el punto de vista del investigador se deben iniciar estrategias de manejo basadas en el potencial terapéutico y la profilaxis. Se realizó una búsqueda bibliográfica detallada sobre los pacientes con OMFP y su asociación con la patología periapical. Los criterios de inclusión incluyen varios estudios realizados sobre los temas anteriores. Descubrimos que se identificaron un total de 300 casos a partir de 150 artículos publicados en literatura en idioma inglés. De estos 150, se filtraron 98, reduciéndose a 52 estudios completamente descargados relacionados con el tema. Finalmente, la perspectiva de un endodoncista debe realizarse de manera excepcional en pacientes con OMFP para lograr el éxito a largo plazo.

Palabras clave(español)

Oral y maxilofacial, patología, endodoncia, periapical, microbioma.

Introduction

The periapical region, comprising the tissues surrounding the tooth apex, is of paramount importance in dental and endodontic practice. Understanding the pathology of this region is crucial for diagnosing and treating a range of dental conditions. Historically, dental infections and periapical lesions have been significant contributors to patient discomfort and tooth loss. With advancements in diagnostic and therapeutic approaches, there is a growing need to synthesize existing knowledge and identify gaps in understanding periapical pathology. The prevalence of periapical lesions and their impact on oral health underscore the necessity for a comprehensive literature review. The primary objective of this literature review is to provide a thorough examination of the current state of knowledge regarding periapical pathology. By synthesizing existing research, we aim to offer insights into the etiology, diagnostic techniques, treatment modalities, and emerging trends in the field. This review seeks to contribute to the broader understanding of periapical pathology among dental professionals, researchers, and educators.

Materials and methods

A comprehensive research was done. Articles from beginning to till date are considered. The literature databases included were pubmed, web of science, google scholar, scopus, medline followed by cross references. Keywords included were periapical pathology, endodontology, oral, dental, lesions. Multi journals involving oral and maxillofacial surgery, oral and maxillofacial pathology, endodontology and oral and maxillofacial medicines were included. Literatures in English language which are fully available were included. The important points include publication

date, author name, journal name, date of issue and keypoints.

Results

Literature search. The vast literature search was ended up in 52 published articles which are fully downloaded in English from various databases. The universal language of science is English. In order to avoid biasing and erroneous decisions, other languages were excluded. Duplicate articles were removed. Articles which were not able to fully download were removed. Key areas included oral and maxillofacial pathology, endodontology, oral microbiology, oral and maxillofacial medicine, etc.

The periapical region.

The periapical region, situated at the apex of a tooth root, is a dynamic area where interactions between dental tissues and surrounding structures occur. Pathology surrounding the apex of a tooth root, or roots, is referred to as periapical disease. This will be interpreted as suggesting that the illness is inflammatory, often due to pulp necrosis. Other diseased entities can be seen in the periapical areas as well, however they are usually linked with vital teeth as opposed to non-vital teeth that have necrotic pulp. (1).

Physiology of the apical periodontium and periradicular tissues. The periodontal ligament, which is a component of the periodontium and connects the root cementum to the surrounding alveolar bone, anchors teeth within the face bones, namely the alveolar bone. During the masticatory function, the periodontal ligament's fibers absorb and transfer stresses between the teeth and bone. In reaction to occlusal stresses, alveolar bone continuously changes physiologically, affecting the quantity, density, and orientation of trabeculae inside the bone. An infection of the tooth pulp that spreads to the root pulp and causes its necrosis is the cause of apical periodontitis.

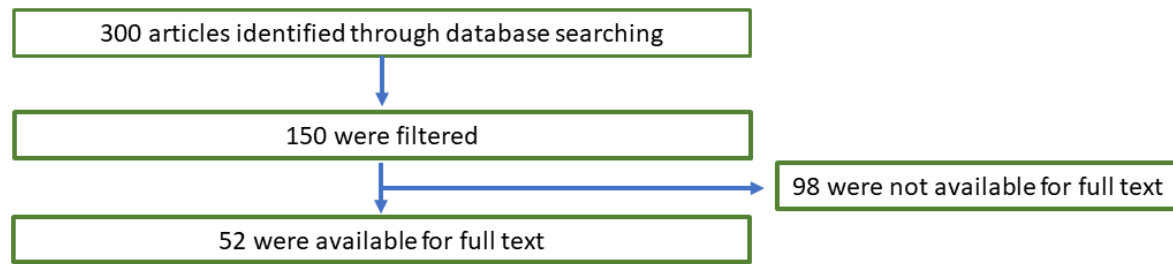


Figure 1. Flowchart of literature search.

The immune system is compromised due to pulp tissue loss, which permits bacteria to enter the alveolar bone through the root canal system. Periapical lesions are of inflammatory origin and can manifest clinically as radicular cysts or apical granulomas. In this case, apical granulomas and radicular cysts are two distinct clinical diseases that result from the same aetiology—pulp necrosis. (2)

Large-scale radicular cyst growth can result in the surrounding jaw bone and periradicular periodontal tissue being destroyed. Radicular cysts may require even mandibular continuous resections in extreme circumstances in order to be properly treated. Radicular cyst epithelium most likely originates from Malassez's epithelial cell remnants (ERM). The ERM cells arise from Hertwig's epithelial root sheath (HERS), which controls the formation of dental roots throughout embryonic development. They are a physiological part of the periodontal ligament. After root growth is finished, the adult organism's periodontal ligament contains essential ERM cells that continue to undergo partial involution of the HERS. Because these ERM cells retain their epithelial features even though they are buried in a mesenchymal matrix, they are essential to the physiology of periradicular tissues. ERM cells have a role in preventing ankylosis and root resorption in addition to being essential for maintaining the periodontal space and the homeostasis of the periodontal ligament. (2,3)

Inflammatory reaction in the periapical area.

Periapical lesions, which most frequently manifest as apical granulomas, are thought to be an immune defence response of the host to stop the transmission of bacterial infections from the root canal to the surrounding tissues. Research on rats and monkeys have demonstrated the critical function that microorganisms in the root canal play in the development and start of periradicular lesions.(4) Macrophages and lymphocytes make up the majority of

immune cells in periapical lesions. When periapical tissue's antigen-presenting cells (APC), such as macrophages, come into contact with microbial components such lipopolysaccharides, they trigger the release of cytokines that either promote or inhibit inflammation. Proinflammatory cytokines such as IL-1 and IL-6 have been demonstrated to function as growth factors for ERM cells, potentially facilitating the creation of radicular cysts. (2,5)

It is acknowledged that immune pathways have a role in the development of radicular cysts in periapical lesions. Research is still needed to fully understand how the host defence mechanisms in apical periodontitis function. When radicular cysts were compared to apical granulomas, macrophages exhibited a notably greater degree of M1-like pro-inflammatory polarization (2,6). Cytokines and growth factors may be used by these cells to connect with ERM cells and encourage their proliferation. The expression of human leukocyte antigen (HLA)-DR, CD83, macrophage colony-stimulating factor (MCSF), and Gal3 appears to be significantly higher in radicular cysts than in apical granulomas, suggesting additional immunological differences between radicular cysts and apical granulomas in addition to macrophages (2,7).

Table 1. An overview ¹⁻⁵²

S.No	Literature	Author	Year	Inference
1	Dental and Oral Pathology	van der Wal, J.E.	2016	Giant cell granulomatous lesion
2	Int J Mol Sci.	Galler et al	2021	pulpitis
3	Periodontol 2000	Xiong et al	2013	Periodontitis
4	Eur Endod J	Karamifar et al	2020	Periapical granuloma
5	J West Afr Coll Surg	Gbadebo et al	2014	Periapical cyst
6	Clin Oral Investig.	Weber M et al	2018	Dentigerous cyst
7	J Endod	Weber M et al	2019	Radicular cyst
8	J Endod	Ramachandran Nair	1987	Periapical granuloma
9	Oral Surg Oral Med Oral Pathol	Bhaskar SN	1966	Periapical cyst
10	Endodontic topics	Abbott PV	2004	Apical periodontitis
11	Int Endod J	Caliskan MA	2004	Periapical granuloma
12	Oral Surg Oral Med Oral Pathol.	Natkin et al	1984	Periapical cyst
13	J Am Dent Assoc.	Lalonde ER	1970	Periapical granuloma
14	Oral Surg Oral Med Oral Pathol.	Morse et al	1973	Periapical cyst
15	J Endod	Pitcher et al	2017	Periapical cyst
16	Arch Oral Biol.	Browne RM	1971	Odontogenic cyst
17	Int Endod J.	Nair PN	1998	Radicular cyst
18	Oral Surg Oral Med Oral Pathol Oral Radiol Endod.	Nair et al	1996	Periapical granuloma
19	J Endod	Sjogren et al	1990	Periapical cyst
20	Int Endod J	Nair et al	1993	Radicular cyst
21	Int Endod J	Ng et al	2011	Periapical granuloma
22	J Endod	Hoan et al	1990	Periradicular lesion
23	Dental Clinics of North America	Mupparapu et al	2020	Periapical cyst
24	Journal of dental research	Math et al	2018	Hypercementosis
25	BMJ case reports	Shoor et al	2014	Hypercementosis
26	Dental Press J Orthod	Consolaro et al	2012	Hypercementosis
27	Skeletal Radiol.	Fenerty et al	2017	Florid cemento-osseous dysplasia:
28	Eur J Dent	Sisman et al	2011	Idiopathic osteosclerosis
29	J Craniofac Surg	De Melo et al	2012	Monostotic fibrous dysplasia
30	J Oral Maxillofac Surg	Haeffs et al	2018	Acute and Chronic Suppurative Osteomyelitis
31	J Istanbul Univ Fac Dent.	Wright JM, Soluk Tekkesin M.	2017	Odontogenic tumours
32	Hum Pathol.	Naggar et al	2017	Head and neck pathology
33	Int Endod J	Ryan et al	2010	Periapical granuloma
34	J South Calif Dent Assoc.	Howell FV, De la Rosa VM.	1968	Periapical cyst
35	Oral Surg Oral Med Oral Pathol Oral Radiol Endod.	Ricucci et al	2006	Periapical granuloma
36	Oral Surg Oral Med Oral Pathol.	Cunningham CJ, Penick EC	1968	Periapical cyst
37	Int Endod J	Cotti et al	2003	Periapical granuloma
38	J Endod	Simon et al	2006	Periapical cyst

Table 1..continued

S.No	Literature	Author	Year	Inference
38	J Endod	Simon et al	2006	Periapical cyst
39	Int Endod J	Kruse et al	2015	Periapical granuloma
40	J Endod	Camps et al	2004	Periapical cyst
41	Aging and Health Research.	Xiang et al	2022	Periapical granuloma
42	Dentomaxillofac Radiol	Parsa et al	2013	Periradicular lesions
43	Endodontic Topics	Siqueira	2005	Periradicular lesions
44	J Conserv Dent.	Chanani A, Adhikari HD.	2017	Periapical cyst
45	J Endod	Tsai et al	2012	Periapical cyst
46	J Endod	Guo et al	2013	Periapical granuloma
47	J Endod	Pope et al	2014	Periapical cyst
48	J Endod	Rosenberg et al	2010	Periapical granuloma
49	Oral Surg Oral Med Oral Pathol Oral Radiol	AAE/AAOMR	2015	Periapical granuloma
50	Eur Radiol	Gaudino et al	2007	Periodontal lesions
51	Clin Oral Invest	Roser et al	2021	Periradicular lesions
52	Oral Surg Oral Med Oral Pathol Oral Radiol.	Musu et al	2016	Bony lesions

are the primary or secondary cause of periapical or periradicular lesions, which are barriers that limit the microorganisms and stop them from spreading into the surrounding tissues. After the bone is resorbed, granulomatous tissue and a thick wall of polymorphonuclear leukocytes (PMN) replace it. In fewer cases, an epithelial plug is present at the apical foramen to prevent pathogens from penetrating into the extra-radicular tissues (4,8). These barriers are impenetrable to a restricted number of endodontic pathogens, but they can be breached by microbial products and toxins, which can then cause and establish periradicular pathosis. The most prevalent clinical manifestations of these diseases are periapical radiolucencies (8).

The majority of radiolucent periradicular lesions fall into one of three categories: dental granulomas, periradicular cysts, or abscesses (9). Another condition brought on by persistently inflamed pulp tissue that develops into chronic apical periodontitis and has a characteristic radiographic appearance is condensing osteitis. With sporadic PDL widening, the periradicular bone appears more radiopaque than healthy bone (10). Histological analyses are able to differentiate between these organisms, providing a conclusive diagnosis for each group (11). If one or more of the following conditions are met, there is a much higher chance of periradicular cyst development: (a) the periradicular lesion involves teeth with necrotic pulps; (b) the lesion is larger than 200 mm²; (c) aspiration results in a straw-coloured fluid or the fluid drains through an access; and (d) the fluid contains cholesterol crystals. According to a report, all of the cases were cysts with radiographic lesion

diameters of at least 200 m². Moreover, lesions with a diameter of 10–20 mm have been shown to have a 60–67% frequency of cysts (12–14). When the lesion volume is taken into account, a cyst has an 80% chance of occurring if it measures more than 247 mm³, and a 60% chance if the root displacement and volume are less than 247 mm³ (15). In 29–43% of periradicular cysts, there are visible cholesterol crystals under a microscope (16). Compared to apical granulomas, these crystals are more prevalent in periradicular cysts (11,16).

Treatment options for periapical lesions include tooth extraction, periapical surgery, and non-surgical root canal therapy. Periapical surgery is the recommended course of therapy if non-surgical measures are judged to be inefficient or challenging. A cable of epithelium may bind true cysts to the root apex; they are closed pathologic entities that are distinct from the apex and have an intact epithelial lining (17,18). They are most likely now autonomous entities that are not likely to react to non-surgical intervention (19). True apical cysts, which cannot be eliminated without surgery (17), are caused by a variety of irritants, including cholesterol crystals and intracanal irritants, which constantly activate the cystic epithelium's basal stem cells (20). The success rate is lower than in instances with smaller lesions (21), despite the possibility that even a big periradicular lesion could possibly directly connect with the root canal system (20) and recover positively after non-surgical therapy with appropriate infection management (11,22).

Classification of periapical lesions. Periapical radiopacities/radiolucencies are the tooth apex

alterations that are seen. However, because periapical radiological findings are caused by diseases not just connected to the tooth but also by diseases surrounding the tooth or bone, which can be observed at the tooth's apex, dentists must interpret these changes with caution. The vitality responses from the teeth can be used to diagnose the most prevalent PA diseases. A crucial first step in obtaining a diagnosis from the differential diagnostic panel of PA radiolucency's is ruling out the tooth-associated diseases. Many factors need to be carefully considered when formulating a radiological differential diagnosis, including: (1) location; (2) locularity; (3) relation to dentition; (4) density of lesion; (5) margin; (6) type of radiological change (radiolucent/radiopaque/mixed); (7) periosteal reaction; (8) cortical integrity; and (9) clinical presentation. (23)

Based on radiolucency and radiopacity, the periapical lesions can be classified as follows: (23)

PA radiopacities-

- **Developmental conditions**
 - o Hypercementosis
 - o Periapical cemento osseous dysplasia (COD)
 - o Focal COD
 - o Florid COD
 - o Idiopathic osteosclerosis (enostosis, dense bone island, bone scar, focal PA osteopetrosis)
 - o Fibrous Dysplasia
 - o Exostoses (tori)
- **Inflammatory disorders**
 - o Condensing osteitis (PA sclerosing osteitis, sclerosing osteitis, focal sclerosing osteitis, focal sclerosing osteomyelitis)
 - o Reactional osteogenesis
 - o PCO
 - o SCO (chronic suppurative osteomyelitis)
 - o Osteomyelitis with proliferative periostitis (Garre osteomyelitis, juvenile chronic osteomyelitis, periostitis ossificans, nonsuppurative ossifying periostitis)
- **Benign tumors**
 - o Cementoblastoma
 - o Osteoblastoma
 - o Osteoma
 - o Osteoid osteoma
 - o Cemento-ossifying fibroma
 - o Compound odontoma
 - o Complex odontoma
- **Mimicking lesions as PA radio-opacities due to superimposition**
 - Malignant and metastatic lesions

- o Supernumerary teeth
- o Sialolith
- o PA radiopacities
- o Developmental
- o Dentigerous cyst
- o Lateral periodontal cyst I
- o nflammatory lesions
- o Apical periodontitis
- o PA abscess
- PA radiolucencies

- **Developmental**
 - o Dentigerous cyst
 - o Lateral periodontal cyst
 - Inflammatory disorders
 - o Apical periodontitis
 - o PA abscess
- **Cystic lesions**
 - o PA cyst
 - o Odontogenic keratocyst
 - o Glandular odontogenic cyst
- **Benign tumors**
 - o Ameloblastoma
- **Malignant tumors**
 - o Ameloblastic carcinoma

Periapical radiopaque lesions

Developmental conditions.

Hypercementosis. A non-neoplastic buildup of extra cementum around the roots of one or more teeth is known as hypercementosis. Idiopathic hypercementosis can also be linked to systemic and/or local causes, including trauma, vitamin A deficiency, developmental problems, and Paget disease of the bone. Recent research has connected ENPP1 and GACI mutations to hypercementosis.(24). Adults are the main population affected, and frequency rises with age. The teeth most commonly afflicted are mandibular molars, which are followed by maxillary and mandibular second premolars. It is usually asymptomatic and generally incidentally detected after radiographic examination. A radiograph of the afflicted tooth reveals intact lamina dura and normal periodontal ligament (PDL) space, along with cemental thickening, frequently in the apical third of the root. Most instances lead to diffuse cemental hyperplasia, which can be mild, moderate, or severe. This causes club-shaped hypercementosis. However, there might be a wide range of presentations, such as numerous cemental spikes, circular cementum hyperplasia hypercementosis with a shirt cuff form, and focal

hypercementosis with localized nodular growth. Other than routine radiographic assessment and follow-up, no treatment is required (25,26).

Periapical cemento-osseous dysplasia. The location of this uncommon, benign fibro-osseous dysplastic process is limited to the apical area of the anterior incisors, particularly in the mandible, setting it apart from other cemento-osseous dysplasias (CODs). The PDL is thought to be the source of the lesions, even if the pathogenesis of CODs is uncertain. In addition to having no malignant relationship and no systematic symptoms, CODs are linked to the coexistence of simple bone cysts, a predisposition for osteomyelitis when exposed to oral infections, and no malignant linkage. When diagnosing PA COD, which primarily affects black women over 40, demographics is important. Between 0.24% and 5.9% of people with PA COD. Recently, a novel link between PA COD and female patients with type neurofibromatosis has been revealed. The majority of CODs are asymptomatic and are linked to extraction sites or critical teeth. The hypovascular nature of the afflicted region makes it susceptible to pathologic fracture and osteomyelitis. If infection is present, symptoms may include purulent mucosal discharge, dull discomfort, and jaw enlargement. According to radiographic results, there are three stages that all CODs appear in: (1) the osteolytic phase, which has radiolucent lesions; (2) the cementoblast phase, which has mixed radiodensity lesions; and (3) the osteogenic phase, which has radiopaque lesions encircled by a narrow radiolucent peripheral halo. The second phase, which contains mixed radiodensity lesions, is the most prevalent stage clinically. When seen on cone-beam computed tomography (CBCT) scans, COD appears as well-defined lesions without any tooth movement. On cortical plates, it may also show signs of thinning and expansion. (23).

Focal cemento-osseous dysplasia. This is a relatively rare, benign fibro-osseous dysplastic condition that is unique from other CODs due to the fact it only affects the apical area of important posterior teeth, particularly those in the mandible. The PDL is thought to be the source of the lesions, even if the aetiology of CODs is uncertain. Simple bone cysts coexisting with CODs are linked to the condition's susceptibility for osteomyelitis in response to oral pathogen exposure, absence of malignant linkage, and lack of systematic symptoms. Black women with a mean age in the mid-30s are the majority affected by focal COD (FCOD). According to a 2008 systematic analysis, people of African and East Asian ancestry are the two primary populations at risk. The clinical results resemble PA COD. Any one or more posterior teeth

might have focal lesions. Radiographic findings and management are similar to PA COD. (27)

Florid cemento-osseous dysplasia. Its spread across various posterior quadrants in the maxilla and mandible in tooth-bearing regions sets it apart from other CODs. It is an uncommon, benign fibro-osseous dysplastic process. While the exact cause of CODs is uncertain, the PDL is thought to be the source of the lesions. The occurrence of simple bone cysts, a predisposition to osteomyelitis when exposed to oral infections, the absence of a malignant connection, and a lack of systematic symptoms are all linked to CODs. Florid COD mostly affects middle-aged and older black women in their fourth and fifth decades. Cases of autosomal dominant family inheritance have been reported in 19 reports; however, no underlying genetic aetiology has been found. The clinical results are comparable to those of FCOD and PA COD. Findings from radiography: The lesions are visible in more than two quadrants, but otherwise, the results are comparable to those of other COD lesions. The management is comparable to FCOD and PA COD.(23)

Idiopathic osteosclerosis (enostosis, dense bone island, bone scar, and focal periapical osteopetrosis)

It is characterized by an increase in jaw bone formation without known cause, thought to be a developmental variant associated with typical bone architecture, and free of systemic or inflammatory diseases. There are no notable demographic disparities based on age or gender. Reports of incidence vary between 2.3% to 9.7%. The mandible's first molar area is the most typical site. These lesions are typically discovered by coincidence, asymptomatic, non-expansile, and connected to a critical tooth. The radiographic findings show a well-defined radiopaque structure that varies in size and shape. It might appear as a circular, elliptical, or irregular shape, and its diameter can range from 2 mm to the full height of the body of the mandible. The majority of lesions happened at the apices of the roots, but they can also appear in between the roots or away from the teeth²⁰; external root resorption is evident in 10–12% of patients. Apart from routine radiographic assessment and follow-up, no treatment is required. (28)

Fibrous dysplasia. These are three manifestations of a localized, benign, non-neoplastic fibro-osseous bone disorder: (1) monostotic, (2) polyostotic, and (3) polyostotic with endocrinopathies. A somatic mutation in the GNAS1 gene is linked to a failure in stem cell development in fibrous dysplasia (FD). In order to differentiate PA lesions, the focus of this section is on monostotic craniofacial FD in its early

phases, which is restricted to the apical area. Malignant transformation is linked to 0.4% of FD, with the craniofacial region being the most often affected place. With a 1 in 4000–10,000 incidence, FD makes up 2.5% of all bone lesions and 7% of all benign bone tumours. Rarely, patients with craniofacial FD manifest in the posterior parts of the maxilla and mandible, are younger, and have little to no preference for the feminine gender. Unilateral involvement with unrestrained physical growth, which can result in severe deformity and asymmetry, is a typical clinical feature. may be linked to dental defects such malocclusion, crowding, or spacing as well as discomfort in the bones. Radiographically presents as a lytic, mixed, or sclerotic, depending on the stage. The presence of a ground-glass looks and weakly defined borders are characteristic radiographic findings with FD of the jaws. Displacement of teeth is present along with loss of lamina dura. Options for therapy include extensive repair following major surgery and lifetime surveillance for recurrence disease with bone contouring. (29)

Exostoses (tori). A variety of benign ectopic bone formations are thought to be variations of normal; these include torus palatinus (TP) on the palate, torus mandibularis (TM) on the lingual side of the mandible, either unilaterally or bilaterally, near the canine or premolar region, and buccal and palatal exostoses, which most frequently occur on the buccal of the maxilla. The aetiology is complex, including environmental, genetic, and systemic variables. Bruxism is frequently linked to other conditions. In early adulthood, TP and TM are prevalent, ranging from 12% to 15%, while buccal and palatal exostoses are relatively uncommon and show a growing age-related correlation. Women are twice as likely as males to have TP, but men are more likely to have TM, buccal, and palatal exostoses. These are asymptomatic, hard, and nontender to palpation and usually diagnosed incidentally on clinical examination. Radiographic findings: radiopaque well-defined lesion that, although not associated with the PA region of teeth, may radiographically mask by superimposition or mimic other existing lesions in the area in a 2-dimensional radiograph. Thus, CBCT imaging may be indicated. (23) Surgical intervention may be required if it interferes with mastication or in prosthesis fabrication.

Inflammatory disorders

Condensing osteitis (periapical sclerosing osteitis, sclerosing osteitis, focal sclerosing osteitis, and

focal sclerosing osteomyelitis) The most often documented radiopaque lesion of the jaws, it is a localized bone response owing to low-grade inflammation and typically linked with the apex of the impacted tooth. It affects 4% to 7% of the general population. There have been documented predilections for women and the first molar area of the mandible. The lesion is frequently non-expansile and asymptomatic. A diagnosis of an odontogenic infection or inflammatory connection is necessary; as a result, clinical examinations may reveal profound cavities or massive restorations. These radiopaque lesions are homogenous, widespread, and centered around the tooth's apex. The primary treatment of option in most situations is nonsurgical endodontic therapy, where most patients show partial or total reversal.(23)

Reactional osteogenesis. The root canal infection in the posterior maxilla's PA areas is the cause of an inflammatory periosteal response in the maxillary sinus. In teeth with apical disease, the bony dimension between the roots and the maxillary sinus is noticeably bigger. These are frequently undetected on radiographic examination and are asymptomatic. A 2-dimensional superimposition of maxillary structures is not necessary to view the extent of involvement with CBCT, which is particularly useful in this evaluation. These are radiopaque, well-defined localized lesions at the apex of involved teeth, varying in size and shape from irregular to round to ovoid. Nonsurgical root canal therapy is the initial course of treatment. If the problem persists, surgical enucleation of the PA lesion is the next step.(23)

Primary chronic osteomyelitis. These are chronic inflammatory conditions that are nonodontogenic, nonsuppurative, and nonbacterial. Their genesis is unclear, and there may be links to genetic, autoimmune, or lack of vascularity. With no discernible gender preference, the peak onset occurs in younger patients between the ages of 10 and 20 and older patients beyond the age of 50. nearly solely affects the mandible. These show persistent intermittent bouts of discomfort, trismus, swelling in the lower jaw, paraesthesia across the lower lip and/or affected area, and swollen regional lymph nodes. They have been present for more than 4 weeks and frequently endure more than 2 years. There is also no pus, fistula, sequestration, history of trauma, radiation, or other risk conditions, and no antibiotic response. The most notable result is medullary sclerosis, which is usually varied manifestations of periosteal (onion-skin) responses, osteolysis, and sclerosis. The origin of this condition is complicated, making management

challenging. A range of surgical and nonsurgical interventions, such as muscle relaxants, antibiotics, hyperbaric oxygen, anti-inflammatory medication therapy, and bisphosphonates, are suggested as therapies.(23)

Secondary chronic osteomyelitis (chronic suppurative osteomyelitis). It is more common than primary chronic osteomyelitis (PCO), secondary chronic osteomyelitis (SCO) is a suppurative chronic inflammatory condition with well-defined aetiology of bacterial invasion from dental infection, trauma, and/or surgery to the affected area. It commonly affects the mandible and has no significant preference in age or gender. It presents for more than 4 weeks exhibiting chronic episodes of pus, abscess, fistula formation, and/or sequestration. Unlike PCO, symptoms usually are resolved earlier than 2 years. Pain and swelling were the most common complaints, followed by paraesthesia and tooth mobility. Radiographically presents the varying presentations of lucent and sclerotic changes with osteolysis, bone sclerosis, sequestration, and/or periosteal reaction. The treatment of the aetiology is important in SCO and usually leads to resolving the condition; treatment includes surgical debridement and antibiotics.(23,30)

Osteomyelitis with proliferative periostitis (garre osteomyelitis, juvenile chronic osteomyelitis, periostitis ossificans, and nonsuppurative ossifying periostitis)

This is a unique variant of juvenile chronic nonsuppurative sclerosing osteomyelitis that has a noticeable thickening of the periosteum and may represent an early-onset form of PCO. A common aetiology is an odontogenic infection that causes pulpal necrosis. This disorder mostly affects the mandible rather than the maxilla, with a mean age of 13 years and no predilection for either gender. It is nearly only observed in children and young adults. Asymmetry and swelling of the face, generally unilateral, are the most prevalent symptoms; discomfort, trismus, and malaise are also present. The aetiology and extent of the illness are better understood with the use of CBCT. Planar radiographs further display the lamellated look of onion skin as a result of modified mature trabecular bone, coarse trabecular bone with broad marrow gaps, and periosteal new bone growth. Management includes elimination of aetiological factors. (23)

Benign tumors

Cementoblastoma. It is an infinitely growing benign neoplastic ectomesenchymal odontogenic

tumor of uncertain aetiology. It is extremely uncommon, making up between 1% and 6.2% of all odontogenic tumors, and it is gender-neutral. Before the age of thirty, young individuals are more likely to experience it. Mandibular premolars and molars are most commonly affected; mandibular first molars account for half of the cases. seldom ever affects impacted or main teeth. Tenderness, discomfort, and swelling are possible signs, as well as cortical plate erosion, perforation, or enlargement. Teeth can still be vital. The radiographic image displays a well-circumscribed radiopaque mass that is continuous, accompanied by a thin radiolucent line surrounding the tooth root, root resorption, a disturbed lamina dura, and a loss of root contour. The whole surgical extraction of the impacted teeth and calcified region is the gold standard of care. Recurrence is frequent when curettage is used alone or when the lesion is not completely removed.(23).

Osteoblastoma. These are primary bone tumours that are benign neoplastic growths that are characterized by an abundance of osteoblasts that frequently develop slowly and have limited capacity for growth. Malignant transformation is uncommon, although aggressive forms sometimes occur. very uncommon, making of only 1% of all primary bone cancers. Location is usually in the mandibular premolar and molar area when it comes to the jaw. Preference for patients under 30 years old, with a peak occurring during the second decade of life, and for men, having a 2:1 male-to-female ratio. The most typical symptoms are swelling that is sensitive to palpation, a dull, agonizing pain that is localized and frequently spontaneous, and cortical bone expansion buccally and/or lingually. In certain instances, pain might not be felt. If present, Aspirin does not reduce pain the way it does in osteoid osteoma. While affected teeth are frequently essential, they might become movable and sensitive to pressure. radiographically presented with a highly diverse look that makes it impossible to identify a single pathognomonic sign; the lesion is frequently bigger than 2 cm, well-defined, and can have tiny calcifications. Its radiodensity ranges from lucent to mixed to opaque. does not need to be related with teeth, but if it is, the tooth is not bonded to the cementum, which might lead to tooth displacement or mobility. Curettage, limited excision, or total resection with margins in normal tissues are possible forms of therapy. More chemotherapy and/or radiation therapy may be needed in aggressive instances. (23)

Osteoma (central). It is a benign, slowly-growing neoplastic tumor that can be centrally (inside the cancellous bone) or peripherally (on the outside of

the bone), proliferating mature cortical or cancellous bone. Osteomas nearly often involve the craniofacial bones and are not usually connected to teeth; frequent sites of presentation include the condyle, posterior mandibular body, and paranasal sinus walls. Keep in mind that a hallmark indicator of Gardner syndrome is numerous mandibular osteomas. Cementoblastoma located at the root apex of the second premolar is visible in the mandibular right premolar PA picture. Because thick cementoblastoma surrounds the apical portion of the root, it is invisible. All osteomas have similar demographics, with a mean age between 40 and 65 years old and a slight predisposition for men. Although they may not cause any symptoms, the majority of isolated jaw central osteomas show clinical signs of enlargement, tooth displacement, and discomfort. appears as a radiopaque, well-defined, homogeneous sclerotic mass on radiography. It could be difficult to distinguish from idiopathic osteosclerosis in the absence of bone growth. Root resorption from the outside is conceivable. Larger, symptomatic, or functionally impaired central osteomas should be surgically excised; smaller, asymptomatic osteomas usually don't need to be treated. (23)

Osteoid osteoma. It is a rare benign neoplastic bone tumor with unknown etiology that is characterized by a central nidus surrounded by sclerotic bone. 80% of cases occur in long bones and less than 1% occur in the jaws. Generally, occurs in young patients under age of 30 years, slightly more in women, with a ratio to men of 1.2:1, and slightly more often in the posterior body of the mandible. A key clinical symptom is severe pain and tenderness, often nocturnal, that is relieved partially or completely with salicylates and nonsteroidal anti-inflammatory drugs. Radiographic findings: usually smaller than 2 cm in size with a radiopaque nidus surrounded by new sclerotic bone formation. When in the jaw, presents as a radiopaque mass that is generally cause root resorption or lead to tooth displacement but not associated with roots of any tooth. Recommended treatment is complete surgical excision and involved tooth if associated.(23)

Cemento-ossifying fibroma. The World Health Organization (WHO) has identified it as a primary bone-forming tumor of the mandible. a benign fibro-osseous tumor with an unclear cause that is thought to be the result of PDL; nonetheless, most instances have a history of trauma to the afflicted region. It primarily affects women in their third and fourth decades; when it manifests, it occurs 70% to 75% of the time in the mandible and does not have a tight relationship with the tooth roots. It manifests as a painless, slowly

expanding bone enlargement that may cause teeth dislocation and facial asymmetry. radiographically manifests as tiny, radiopaque calcifications with well-circumscribed, radiolucent unilocular lesions; the inferior cortex is typically displaced downward. might result in root divergence. Curettage or nucleation is the suggested course of therapy, having a recurrence rate lower than 5%. (23,31)

Compound odontoma. This is a kind of odontogenic tumor, slow-growing and composed of both epithelial and ectomesenchymal cells. It forms many "odontoids" or "denticles," which are miniature teeth with well-ordered and well-formed dental structures. Although the exact cause is unknown, trauma, illness, and/or heredity may have an impact. most frequently detected in the 2nd and 3rd decades of life, with no preference for gender and a predilection for the anterior maxilla area. Patients may exhibit symptoms such as jaw expansion, discomfort from expansion, late eruption of permanent teeth, persisting primary teeth, devitalization, and/or edema. These conditions are frequently symptomatic and discovered by chance when radiography is used to check for unerupted teeth. Radiographically presents with a radiolucent material around a radiopaque mass, typically ranging in size from 5 to 30 mm, composed of 4 to 21 odontoids with radiopacity equivalent to those of teeth. could lead to neighbouring tooth resorption. Total surgical removal of the encapsulated tumour is the course of therapy; as the patient ages, tooth extraction is more advised. (23)

Complex odontoma. It is an uneven and disorganized mass of dental tissues that is a slow-growing neoplastic mixed (epithelial as well as ectomesenchymal) odontogenic tumour. Although the exact cause is unknown, trauma, illness, and/or heredity may have an impact. usually located in the posterior jaw, particularly in the space between the roots of emerged teeth in the mandibular second and third molars. Most often diagnosed in the second and third decades, findings have varied on gender preference without reaching an agreement. Frequently asymptomatic, patients are identified by chance when radiography is used to check for unerupted teeth. Patients may exhibit devitalization, a postponed eruption of permanent teeth, persisting primary teeth, discomfort, or oedema. Appears as a radiopaque mass on radiographs, which can be irregular, solitary, numerous, and have different radiopacities. May result in the resorption of adjacent teeth. The recommended course of treatment is the surgical removal of the encapsulated tumour in its entirety; the likelihood of

undergoing tooth extraction increases with the patient's age. (23)

Malignant and Metastatic Lesions Appearing as Periapical Radiopacities. These are metastatic lesions that result from a previous primary cancer that occurred somewhere else (breast, prostate, etc.). They can resemble both osteogenic regions inside the radiolucencies and osteolytic areas periapically. On intraoral and panoramic radiographs, as well as computed tomography (CT) scans, these lesions seem irregular and ill-defined. On fludeoxyglucose F 18 (FDG)-PET or sodium fluoride F 18-PET scans, these lesions light up. These lesions in the jaw are often found incidentally during radiological exams; a clinical examination may indicate an intraoral tumor or an ulcerated region. There is involvement of lymph nodes. A biopsy is necessary to confirm the diagnosis. On planar and tomograms, irregular radiolucent regions are among the radiographic findings. Uneven lytic regions can occasionally be seen scattered across thick opacifications on CT or CBCT images. A head and neck oncology team has to assess this, just like they would any malignant tumor. The initial course of treatment for metastatic lesions is frequently surgery, which is followed by radiation therapy or chemotherapy.

Supernumerary teeth. Because they are superimposed in the area of the root apices, situations like supernumerary teeth—both in the anterior maxillary region (mesiodens) and the posterior maxillary and mandibular regions —can resemble PA pathoses. After reviewing the literature, Albert and Mupparapu⁶⁹ presented a categorization scheme for mesiodens based on how they look and are positioned on radiographs. They are inadvertently discovered during radiographic examinations. Once identified, relevant radiographic analyses can be carried out. They present as PA thick opacifications on intraoral radiographs, but unless the tooth is smaller or deformed like a mesiodens, the diagnosis is typically ruled out by the existence of follicular space. In similar circumstances, a small-volume CBCT is advised for a precise diagnosis and tooth localization. Once located within the anterior maxillary region, mesiodens are visible in the alveolar bone. They can also occasionally be observed at the level of the nasal fossa floor or in the nasopalatine canal. Because the teeth are flipped in these situations, the eruption points toward the nasal fossa's floor. These are rather uncommon incidents. The teeth are extracted via surgery after being located and identified.

Sialolith. Submandibular sialoliths, which simulate disease, are overlaid on mandibular anterior as well as posterior radiographs. A thorough medical

history and physical examination may reveal the existence of a sialolith, but it may also be entirely asymptomatic, in which instance it is an unintentional discovery. Examining the kind of opacification is necessary if PA radiographs reveal a circular opacity close to a tooth's apex. The likelihood that the teeth are superimposed is considered if they are essential. In accordance with the degree of calcification, sialoliths can often be rounded or concentric opacifications with smooth edges that vary in size. an occlusal radiograph reveals the sialolith when it is suspected. A substitute for occlusal radiographs, which have been unavailable since the introduction of digital radiography, is a narrow field-of-view computed tomography (CBCT) scan of the affected mandibular side. This can occasionally be a dystrophic calcification in the mandibular floor or a calcified lymph node. Following identification and localization by specialist methods such as sialography (in cases when the salivary gland does not show signs of inflammation) or sialendoscopy, surgical excision is carried out using lithotripsy is performed. (23)

Periapical radiolucencies Developmental:

Lateral periodontal cyst. Less than 1% of recorded occurrences of odontogenic cysts are lateral periodontal cysts, which typically arise on the lateral surface of important teeth. The mandibular incisor-canine-premolar region is where the majority of lateral periodontal cysts are found. When seen via radiography, lateral periodontal cysts appear as a single, unicular, radiolucent lesion between a tooth's roots or on the side of the tooth. For lateral periodontal cysts, surgical enucleation combined with tooth preservation is an acceptable course of therapy. Recurrence is not common. It has been found that the multiloculated variety known as botryoid odontogenic cysts exhibits a greater recurrence rate compared with its unilocular counterpart.(23)

Inflammatory lesions

Apical periodontitis, periapical abscess. These lesions are brought on by a spectrum of inflammation that affects the PA region of teeth and is brought on by microbial pulpal infection. The most common inflammatory lesion connected to teeth within the jaws is apical periodontitis. It is possible to categorize apical periodontitis as asymptomatic or symptomatic; percussion and tooth palpation tests produce negative

findings in the former case and often positive results for the latter. However, pulp sensitivity testing for both circumstances provide negative findings. The PA PDL may show acute inflammation in the early stages of PA inflammation without the development of an abscess. This localized change might lead to the establishment of an abscess. Radiographs of apical periodontitis may reveal an enlarged PDL space. A radiolucent region surrounding the root apex is seen on radiographs when an abscess forms during a protracted case of apical periodontitis. Prolonged infection of the root canal system results in the inflammatory illness known as apical periodontitis. Either a root canal or tooth extraction is the suggested course of action for getting rid of the germs and dead nerve. Antibiotics should only be used in cases of serious infection that have permeated the surrounding tissues from the tooth. (23)

Cystic Lesions Periapical (radicular) cyst. An inflammatory cyst connected to a tooth that is not important is called a radicular cyst. These cysts are the most prevalent type of odontogenic cysts. Although a lateral radicular cyst may be connected to a lateral root canal, radicular cysts are most frequently related with the apex of the tooth. A nonvital tooth is invariably linked to radicular cysts. The apex of a tooth frequently has a clearly defined radiolucent lesion seen on radiographs. Adjacent teeth's roots may be reabsorbed or dislodged by radicular cysts. Radicular cysts can be treated with both nonsurgical root canal treatments and surgical methods like apicoectomy.(23)

Odontogenic keratocyst. The third most prevalent type of jaw cysts are odorogenogenic keratocysts. The mandibular molar area is where odontogenic keratocysts are most frequently seen. The size of an odontogenic keratocyst can vary; it might be as little as a dentigerous cyst-like lesion encircling the crown of an unerupted tooth, or as big as a lesion that deforms the face and destroys surrounding tissues. These lesions have a propensity to develop posteroanteriorly, which prevents cortical extension. Compared to other odontogenic cysts, odontogenic keratocysts often have a more aggressive development style and a greater recurrence rate. However, inadequate removal or the existence of satellite (daughter) cysts may be the cause of recurrence. Therapy options include marsupialization, enucleation (with or without peripheral ostectomy, Carnoy solution therapy), or resection.

Glandular odontogenic cyst. A developing cyst with characteristics similar to glandular differentiation. Around one percent of odontogenic cysts are glandular in nature. There's a preference for the jaw. But it

appears that the dog is frequently implicated in the maxilla. The most frequent concerns that were presented were swelling and expansion. On radiography, glandular odontogenic cysts appear as a distinct unilocular or multilocular radiolucency's connected to tooth roots; it is uncommon for this relationship to be seen in connection with impacted teeth. Recurrence of glandular odontogenic cysts is common, particularly after simple enucleation of the tumour (23).

Benign tumors

Ameloblastoma. These are benign epithelial odontogenic neoplasm with unrestricted growth potential that grows slowly. With the exception of odontomas, ameloblastomas constitute the most prevalent odontogenic tumors. Compared to white people, African Americans appear to have a 5-fold higher overall risk of illness in the US. A tumor can be linked to an unerupted tooth and frequently manifests as an asymptomatic posterior mandibular enlargement. Lingual and buccal enlargement are frequently seen. Corticated multilocular (soapbubble) radiolucency is frequently seen on radiographs. Because of the unbridled capacity for growth and propensity for recurrence, segmental or marginal excision is necessary for surgical care. Significantly greater recurrence rates are seen when enucleation is the only treatment used (23).

Malignant tumors

Ameloblastic carcinoma. An uncommon, cancerous variant of ameloblastoma. This is a histologically benign ameloblastoma that has metastasized to distant places; it should not be confused with metastasizing ameloblastoma. Metastasizing ameloblastoma has been classified as a kind of conventional ameloblastoma and separated from ameloblastic carcinoma in the most recent WHO Classification of Head and Neck Tumours. The incidence rate per 10 million people per year was 1.79, with a preponderance of Black and Male individuals. With 17.6 years of survival overall. The posterior mandible is the most often affected place. Pain and swelling are frequently the initial signs and symptoms. While some instances develop in ameloblastomas that already exist, most cases emerge de novo. Ameloblastic carcinomas might appear radiographically as indistinguishable radiolucency's from benign ones or as poorly defined,

irregular radiolucency's consistent with a malignancy. Generally regarded as a radioresistant tumour, complete surgical removal is considered as the first line of treatment.(23,32)

Differential diagnosis of various pa lesions

Examining periapical biopsy specimens has allowed researchers to determine the frequency and predominance of inflammatory alterations caused by root canal infection, such as granulomas and periapical cysts (33). There has been minimal success in precisely diagnosing the lesion and determining the type of the periapical pathosis prior to surgery. While several techniques have been suggested, including albumin tests (14), Papanicolaou smears (34), periapical radiography (35), contrast media (36), and real-time ultrasound imaging (37), these have not shown to be reliable. The use of other imaging systems, such as cone beam computed tomography (CBCT), with high specificity and excellent accuracy, can increase the likelihood of a more accurate preoperative diagnosis, even though the postoperative histopathological examination continues to be a standard procedure for an assessment of the nature of the lesion (38,39).

A CT scan can be used to distinguish between a granuloma and a cyst based on their relative densities. A preoperative screening strategy with favourable sensitivity (58%) and specificity (90.8%) for cysts was also presented, based on certain CBCT radiologic criteria. To evaluate the effectiveness of the therapy, a gray level correction approach was also used. (40)

Typically, granulomas consist of solid soft tissue, whereas cysts include a liquid, semi-solid cystic region. Therefore, in order to accurately diagnose these lesions, the radiographic lesion's least dense region has to be quantified. It is feasible to distinguish between fluid or empty regions and soft tissues by measuring the grey value (40).

With a variable degree of peripheral cortication, periapical abscesses share characteristics with periapical granulomas and periapical cysts, making it challenging to differentiate between the three (40). Though the early stages of periapical abscesses frequently do not present with these features, cortical erosion or perforation shown in CBCT tests and the presence of edema may give further information in identifying abscesses. While histopathologic evaluation is the gold standard for distinguishing between periapical radiolucencies with endodontic origin, it is rarely performed because non-surgical endodontic treatment frequently resolves these diseases, making

the distinction between a cyst and a granuloma unnecessary. All three of these lesions can be treated by extraction, periradicular surgery, root canal (re)treatment, or a combination of these (41)

The origin, pathophysiology, and radiological features of scar tissue have been the subject of several research. Radiographic characteristics of fibrous scar tissue are comparable to those of periapical cysts and granulomas. It is possible for fibrous scar tissue to heal instead of bone, particularly following endodontic surgery. The fibrous tissue appears spherical and punched out, and there is little discomfort in the region when a significant percentage of the cortical plates and bone periosteum are removed. It seems normal on radiography and doesn't require any further care. While scar tissue identification may only be confirmed by histopathology, some radiographic findings may aid in their identification. Scar tissue is suggested by decreasing rarefaction with an irregular contour extending angularly into the periodontal space, which is positioned asymmetrically with respect to the root apex and may or may not have visible internal bone structures. Lamina dura, which divides the tooth from the rarefaction, may be present around the apex (4).

When diagnosing a solid lesion or cavity from one that is fluid-filled, the CBCT may be a useful diagnostic tool. The center region or the tip of the root is where this approach is most accurate (42). To increase the accuracy of CBCT, the entirety of radiolucency should be sensibly searched for the least dense area, or the most lucent area. This region represents a semi-solid or fluid-filled area, presumably a genuine cyst (cavitated lesions) or the lumen of a bay, if the CBCT picture has a negative grayscale value (43). While the number of projections, hard beaming, scattering, and field of view and spatial resolution selections can all easily impact the grayscale values (42), the CBCT method reveals lower grayscale values that indicate a fluid-filled cavity without revealing the epithelial lining. It may aid the physician in predicting the course of treatment if it produces a positive grayscale result, indicating that the lesion is either a granuloma or an epithelialized granuloma. The hollow that contains fluid and the semi-solid material in the lumen are examples of areas with reduced density that may be distinguished from solid lesions in the soft tissue by using the CBCT approach (38).

When apical lesions have an average diameter of at least 5 mm, CBCT can distinguish between granulomas and periapical cysts with a reasonable degree of accuracy (44). Only 26–48% of periapical radiographs may accurately diagnose a periapical lesion (45). When periapical pathosis is revealed, CBCT is a

more accurate tool than PA radiographs. When diagnosing apical periodontitis, CBCT is more accurate than PA radiographs, especially when the lesions measure more than 1.4 mm (45). CBCT is a non-invasive technique that may distinguish between granulomas and periapical cysts (38), and it has strong preoperative diagnostic efficacy for cysts. High-resolution scans are required for specialized diagnostic activities like endodontics or the imaging of tiny bone structures (46).

The possibility of false-positive results of PDL widening in relatively healthy teeth, indicating PA lesions, is one of the disadvantages of CBCT. Its use is also debatable in some circumstances because of worries about patient radiation exposure, scanning time, and cost in comparison to traditional radiography methods. The CBCT picture quality can be impacted by materials having a high atomic number. The 3D volumes may be difficult to perceive in full due to poor contrast and picture quality (4,47). One research found that because there are so many potential diagnoses for apical pathosis, including granulomas, lesions that resemble granulomas, cysts, lesions that resemble cysts, and other lesions, CBCT may not be a good diagnostic tool (48).

The American Association of Endodontists (AAE) states that CBCT "should only be used when alternate imaging modalities or lower-dose conventional radiography cannot adequately answer the question for which imaging is required" (49).

The radiation-free imaging technique known as magnetic resonance imaging (MRI) offers excellent contrast between soft tissues. Dental MRI is gaining a lot of attention because of the high field strength, distinctive coil systems, and ideal sequence approaches that provide high-quality pictures. The MRI has been used to characterize periapical lesions, and it may also be a useful non-invasive method to distinguish between condensing osteitis, periapical cysts/granulomas, and apical periodontitis (4,50). When it comes to accurately estimating the lesion boundary, X-ray-based approaches are not perfect and have limited effectiveness. However, MRI is a more reliable non-invasive diagnostic method for apical periodontitis and provides a more precise estimate of the lesion's proximity to adjacent structures. If soft tissue-associated pathosis in the head and neck region is to be diagnosed, MRI is a better diagnostic method than CT. Additionally, MRI may be utilized to determine the kind of periapical lesions. Still, there are several drawbacks to this approach. For a satisfactory resolution, a longer scanning time is needed. Due to their lack of MRI signals, enamel and dentin are difficult to visualize.

Image clarity is impacted by imaging artifacts resulting from metal restorations, high atomic number materials, and patient motion.(51)

There are several uses for echography, often known as ultrasonography, in medicine as a real-time ultrasound imaging method. It depends on ultrasonic wave reflection. Endodontic periradicular lesions can be assessed by the echo-graphic examination. The ultrasonic vibrations are reflected differently by various bodily tissues due to their distinct acoustic qualities. Since bone reflects everything, this method can only be applied through bony windows or in places where the architecture of the bone has altered. "Dis-homogeneous echo" is seen in regions with varying tissue types. According to some research, echography is a dependable method that may be used in addition to traditional radiography to identify and monitor periapical lesions. Additionally, it can provide some information on the vascularization, size, and contents of the lesion, which can be useful in differentiating between endodontic and other diseases affecting the maxillary bone (37). As compared to digital radiography (55.6%) and traditional radiography (47.6%), ultrasonography was shown to have a better percentage accuracy of 95.2% in the diagnosis of periradicular lesions. As an invaluable diagnostic tool for assessing the type of intra-osseous lesions in the jaws, ultrasound is ideally suited to be considered as an additional imaging modality in routine dentistry and maxillofacial surgery. This is especially true for differentiating between granulomas and periradicular cysts, which are echogenic in grayscale (52). If a lesion contains mineralized tissue, like an ossifying fibroma or dentigerous cyst, which may also act as a barrier to ultrasound waves passing through the tissue, then ultrasonography examination is inconclusive. However, it can help detect vascular lesions, malignancies, cysts, apical granulomas, and apical periodontitis. Ultrasonography has been shown to be clinically valuable in the detection of bone lesions (52). The fact that pocket cysts cannot be distinguished from real cysts by ultrasonography is remarkable. Ultrasonography diagnosis of intra-osseous lesions requires erosion of the cortical plate (4,52).

Conclusion

There is a direct relationship between oral and maxillofacial infections and dental biofilm. Lie threatening complications might arise due to the mode of spread through bone marrow and fascial spaces. Early diagnosis might help in management of such lesion and provide a better quality of life to the patients.

Conflict of interest

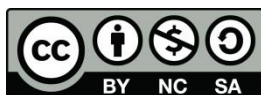None to declare.

Referencias

- van der Wal, J.E. Pulse Granuloma. In: Slootweg, P.J. (eds) Dental and Oral Pathology. Encyclopedia of Pathology. Springer, Cham. 2016[[Google Scholar](#)]
- Galler KM, Weber M, Korkmaz Y, Widbiller M, Feuerer M. Inflammatory Response Mechanisms of the Dentine-Pulp Complex and the Periapical Tissues. Int J Mol Sci. 2021;22: 1480. [[PubMed](#)] [[Google Scholar](#)]
- Xiong J, Gronthos S, Bartold PM. Role of the epithelial cell rests of Malassez in the development, maintenance and regeneration of periodontal ligament tissues. Periodontol 2000. 2013; 63: 217–33. [[PubMed](#)] [[Google Scholar](#)]
- Karamifar K, Tondari A, Saghir MA. Endodontic Periapical Lesion: An Overview on the Etiology, Diagnosis and Current Treatment Modalities. Eur Endod J. 2020; 5: 54–67. [[PubMed](#)] [[Google Scholar](#)]
- Gbadebo SO, Akinyamaju AO, Sulaiman AO. Periapical pathology: comparison of clinical diagnosis and histopathological findings. J West Afr Coll Surg. 2014; 4: 74–88. [[PubMed](#)] [[Google Scholar](#)]
- Weber M, Schlittenbauer T, Moebius P, Büttner-Herold M, Ries J, Preidl R, Geppert CI, Neukam FW, Wehrhan F. Macrophage polarization differs between apical granulomas, radicular cysts, and dentigerous cysts. Clin Oral Investig. 2018; 22: 85–394. [[PubMed](#)] [[Google Scholar](#)]
- Weber M, Ries J, Büttner-Herold M, Geppert CI, Kesting M, Wehrhan F. Differences in Inflammation and Bone Resorption between Apical Granulomas, Radicular Cysts, and Dentigerous Cysts. J Endod. 2019; 45: 1200–8. [[PubMed](#)] [[Google Scholar](#)]
- Ramachandran Nair PN. Light and electron microscopic studies of root canal flora and periapical lesions. J Endod. 1987;13: 29–39. [[PubMed](#)] [[Google Scholar](#)]
- Bhaskar SN. Oral surgery--oral pathology conference No. 17, Walter Reed Army Medical Center. Periapical lesions--types, incidence, and clinical features. Oral Surg Oral Med Oral Pathol. 1966; 21: 657–71. [[PubMed](#)]
- Abbott PV. Classification, diagnosis and clinical manifestations of apical periodontitis. Endodontic Topics. 2004; 8: 36–54. [[Google Scholar](#)]
- Calışkan MK. Prognosis of large cyst-like periapical lesions following nonsurgical root canal treatment: a clinical review. Int Endod J. 2004 ; 37: 408–16. [[PubMed](#)]
- Natkin E, Oswald RJ, Carnes LI. The relationship of lesion size to diagnosis, incidence, and treatment of periapical cysts and granulomas. Oral Surg Oral Med Oral Pathol. 1984 Jan;57(1):82–94. [[PubMed](#)] [[Google Scholar](#)]
- Lalonde ER. A new rationale for the management of periapical granulomas and cysts: an evaluation of histopathological and radiographic findings. J Am Dent Assoc. 1970; 80: 1056–9. [[PubMed](#)] [[Google Scholar](#)]
- Morse DR, Patnik JW, Schacterle GR. Electrophoretic differentiation of radicular cysts and granulomas. Oral Surg Oral Med Oral Pathol. 1973; 35: 249–64. [[PubMed](#)] [[Google Scholar](#)]
- Pitcher B, Alaqla A, Noujeim M, Wealleans JA, Kotsakis G, Chrepa V. Binary Decision Trees for Preoperative Periapical Cyst Screening Using Cone-beam Computed Tomography. J Endod. 2017; 43: 383–8. [[PubMed](#)] [[Google Scholar](#)]
- Browne RM. The origin of cholesterol in odontogenic cysts in man. Arch Oral Biol. 1971; 16: 107–13. [[PubMed](#)] [[Google Scholar](#)]
- Nair PN. New perspectives on radicular cysts: do they heal? Int Endod J. 1998; 31: 155–60. [[PubMed](#)] [[Google Scholar](#)]
- Ramachandran Nair PN, Pajarola G, Schroeder HE. Types and incidence of human periapical lesions obtained with extracted teeth. Oral Surg Oral Med Oral Pathol Oral Radiol Endod. 1996; 81: 93–102. [[PubMed](#)] [[Google Scholar](#)]
- Sjogren U, Hagglund B, Sundqvist G, Wing K. Factors affecting the long-term results of endodontic treatment. J Endod. 1990; 16: 498–504. [[Google Scholar](#)]
- Nair PN, Sjögren U, Schumacher E, Sundqvist G. Radicular cyst affecting a root-filled human tooth: a long-term post-treatment follow-up. Int Endod J. 1993; 26: 225–33. [[PubMed](#)] [[Google Scholar](#)]
- Ng YL, Mann V, Gulabivala K. A prospective study of the factors affecting outcomes of nonsurgical root canal treatment: part 1: periapical health. Int Endod J. 2011; 44: 583–609. [[PubMed](#)] [[Google Scholar](#)]
- Hoehn MM, LaBounty GL, Strittmatter EJ. Conservative treatment of persistent periradicular lesions using aspiration and irrigation. J Endod. 1990; 16: 182–6. [[PubMed](#)] [[Google Scholar](#)]
- Mupparapu M, Shi KJ, Ko E. Differential Diagnosis of Periapical Radiopacities and Radiolucencies. Dental Clinics of North America. 2020; 64: 163–89. [[PubMed](#)] [[Google Scholar](#)]
- Thumbigere-Math V, Alqadi A, Chalmers NI, Chavez MB, Chu EY, Collins MT, Ferreira CR, FitzGerald K, Gafni RI, Gahl WA, Hsu KS, Ramnitz MS, Somerman MJ, Ziegler SG, Foster BL. Hypercementosis Associated with ENPP1 Mutations and GACI. J Dent Res. 2018; 97: 432–41. [[PubMed](#)] [[Google Scholar](#)]
- Shoor H, Sujir N, Mutalik S, Pai KM. Hypercementosis: a rare finding in a patient with systemic lupus erythematosus. BMJ Case Rep. 2014; 26; 2014:bcr2013202370. [[PubMed](#)] [[Google Scholar](#)]
- Consolaro A, Consolaro RB, Francischone LA. Cementum, apical morphology and hypercementosis: a probable adaptive response of the periodontal support tissues and

- potential orthodontic implications. *Dental Press J Orthod.* 2012; 17: 21–30. [\[PubMed\]](#) [\[Google Scholar\]](#)
27. Fenerty S, Shaw W, Verma R, Syed AB, Kuklani R, Yang J, Ali S. Florid cemento-osseous dysplasia: review of an uncommon fibro-osseous lesion of the jaw with important clinical implications. *Skeletal Radiol.* 2017; 46: 581–90. [\[PubMed\]](#) [\[Google Scholar\]](#)
 28. Sisman Y, Ertas ET, Ertas H, Sekerci AE. The frequency and distribution of idiopathic osteosclerosis of the jaw. *Eur J Dent.* 2011; 5: 409–14. [\[PubMed\]](#) [\[Google Scholar\]](#)
 29. De Melo WM, Sonoda CK, Hochuli-Vieira E. Monostotic fibrous dysplasia of the mandible. *J Craniofac Surg.* 2012; 23: e452-454. [\[PubMed\]](#) [\[Google Scholar\]](#)
 30. Haeffs TH, Scott CA, Campbell TH, Chen Y, August M. Acute and Chronic Suppurative Osteomyelitis of the Jaws: A 10-Year Review and Assessment of Treatment Outcome. *J Oral Maxillofac Surg.* 2018; 76: 2551–8. [\[PubMed\]](#) [\[Google Scholar\]](#)
 31. Wright JM, Soluk Tekkesin M. Odontogenic tumors: where are we in 2017 ?. *J Istanbul Univ Fac Dent.* 2017; 51(3 Suppl 1): S10–30. [\[PubMed\]](#) [\[Google Scholar\]](#)
 32. El-Naggar AK, Chan JKC, Takata T, Grandis JR, Slootweg PJ. The fourth edition of the head and neck World Health Organization blue book: editors' perspectives. *Hum Pathol.* 2017; 66: 10–2. [\[PubMed\]](#) [\[Google Scholar\]](#)
 33. Becconsall-Ryan K, Tong D, Love RM. Radiolucent inflammatory jaw lesions: a twenty-year analysis. *Int Endod J.* 2010; 43: 859–65. [\[PubMed\]](#) [\[Google Scholar\]](#)
 34. Howell FV, De la Rosa VM. Cytologic evaluation of cystic lesions of the jaws: a new diagnostic technique. *J South Calif Dent Assoc.* 1968; 36: 161–6. [\[PubMed\]](#) [\[Google Scholar\]](#)
 35. Ricucci D, Mannocci F, Ford TRP. A study of periapical lesions correlating the presence of a radiopaque lamina with histological findings. *Oral Surg Oral Med Oral Pathol Oral Radiol Endod.* 2006; 101: 389–94. [\[PubMed\]](#) [\[Google Scholar\]](#)
 36. Cunningham CJ, Penick EC. Use of a roentgenographic contrast medium in the differential diagnosis of periapical lesions. *Oral Surg Oral Med Oral Pathol.* 1968; 26: 96–102. [\[PubMed\]](#) [\[Google Scholar\]](#)
 37. Cotti E, Campisi G, Ambu R, Dettori C. Ultrasound real-time imaging in the differential diagnosis of periapical lesions. *Int Endod J.* 2003; 36: 556–63. [\[PubMed\]](#) [\[Google Scholar\]](#)
 38. Simon JHS, Enciso R, Malfaz JM, Roges R, Bailey-Perry M, Patel A. Differential diagnosis of large periapical lesions using cone-beam computed tomography measurements and biopsy. *J Endod.* 2006; 32: 833–7. [\[PubMed\]](#) [\[Google Scholar\]](#)
 39. Kruse C, Spin-Neto R, Wenzel A, Kirkevang LL. Cone beam computed tomography and periapical lesions: a systematic review analysing studies on diagnostic efficacy by a hierarchical model. *Int Endod J.* 2015; 48: 815–28. [\[PubMed\]](#) [\[Google Scholar\]](#)
 40. Camps J, Pommel L, Bukiet F. Evaluation of periapical lesion healing by correction of gray values. *J Endod.* 2004; 30: 762–6. [\[PubMed\]](#) [\[Google Scholar\]](#)
 41. Qi Xiang, Northridge Mary E., Hu Mengyao, Wu Bei. Oral health conditions and COVID-19: A systematic review and meta-analysis of the current evidence. *Aging and Health Research.* 2022; 2: 100064. [\[PubMed\]](#) [\[Google Scholar\]](#)
 42. Parsa A, Ibrahim N, Hassan B, Motroni A, van der Stelt P, Wismeijer D. Influence of cone beam CT scanning parameters on grey value measurements at an implant site. *Dentomaxillofac Radiol.* 2013; 42: 79884780. [\[PubMed\]](#) [\[Google Scholar\]](#)
 43. Siqueira JF. Reaction of periradicular tissues to root canal treatment: benefits and drawbacks. *Endodontic Topics.* 2005; 10: 123–47. [\[Google Scholar\]](#)
 44. Chanani A, Adhikari HD. Reliability of cone beam computed tomography as a biopsy-independent tool in differential diagnosis of periapical cysts and granulomas: An In vivo Study. *J Conserv Dent.* 2017; 20: 326–31. [\[PubMed\]](#) [\[Google Scholar\]](#)
 45. Tsai P, Torabinejad M, Rice D, Azevedo B. Accuracy of cone-beam computed tomography and periapical radiography in detecting small periapical lesions. *J Endod.* 2012; 38: 965–70. [\[PubMed\]](#) [\[Google Scholar\]](#)
 46. Guo J, Simon JH, Sedghizadeh P, Soliman ON, Chapman T, Enciso R. Evaluation of the reliability and accuracy of using cone-beam computed tomography for diagnosing periapical cysts from granulomas. *J Endod.* 2013; 39: 1485–90. [\[PubMed\]](#) [\[Google Scholar\]](#)
 47. Pope O, Sathorn C, Parashos P. A comparative investigation of cone-beam computed tomography and periapical radiography in the diagnosis of a healthy periapex. *J Endod.* 2014; 40: 360–5. [\[PubMed\]](#) [\[Google Scholar\]](#)
 48. Rosenberg PA, Frisbie J, Lee J, Lee K, Frommer H, Kottal S, Phelan J, Lin L, Fisch G. Evaluation of pathologists (histopathology) and radiologists (cone beam computed tomography) differentiating radicular cysts from granulomas. *J Endod.* 2010; 36: 423–8. [\[PubMed\]](#) [\[Google Scholar\]](#)
 49. Special Committee to Revise the Joint AAE/AAOMR Position Statement on use of CBCT in Endodontics. AAE and AAOMR Joint Position Statement: Use of Cone Beam Computed Tomography in Endodontics 2015 Update. *Oral Surg Oral Med Oral Pathol Oral Radiol.* 2015; 120: 508–12. [\[Google Scholar\]](#)
 50. Gaudino C, Cosgarea R, Heiland S, Csernus R, Beomonte Zobel B, Pham M, et al. MR-Imaging of teeth and periodontal apparatus: an experimental study comparing high-resolution MRI with MDCT and CBCT. *Eur Radiol.* 2011; 21: 2575–83. [\[PubMed\]](#) [\[Google Scholar\]](#)
 51. Roser C, Hilgenfeld T, Sen S, Badrow T, Zingler S, Heiland S, Bendszus M, Lux CJ, Juerchott A. Evaluation of magnetic resonance imaging artifacts caused by fixed orthodontic CAD/CAM retainers: an in vitro study. *Clin Oral Investig.* 2021; 25: 1423–31. [\[PubMed\]](#) [\[Google Scholar\]](#)
 52. Musu D, Rossi-Fedele G, Campisi G, Cotti E. Ultrasonography in the diagnosis of bone lesions of the jaws: a systematic review. *Oral Surg Oral Med Oral Pathol Oral Radiol.* 2016; 122: e19-29. [\[PubMed\]](#) [\[Google Scholar\]](#)

Como citar este artículo.
Parasuraman V, Shunmugavelu K,
Dhinakaran EC Endodontic
microbiota from oral and
maxillofacial perspective–A
systematic review. *Avan Biomed*
2024; 13: 9-25.



Avances en Biomedicina se distribuye
bajo la Licencia Creative Commons
Atribución-NoComercial-CompartirIgual
4.0 Venezuela, por lo que el envío y la
publicación de artículos a la revista son
completamente gratuitos.



<https://me-qr.com/V9ImCRxi>